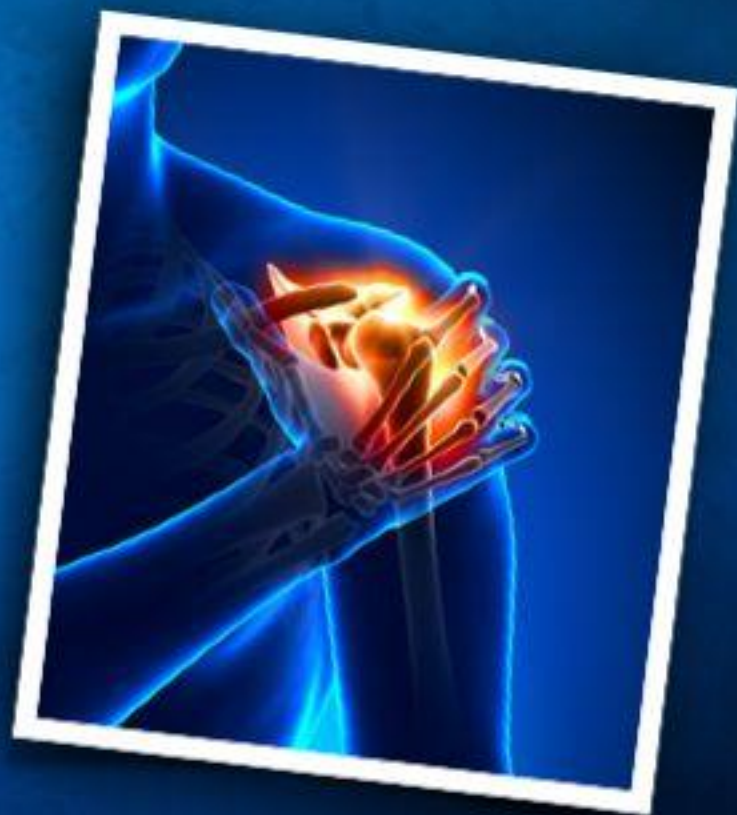

DOR NO OMBRO

SEMIOLOGIA

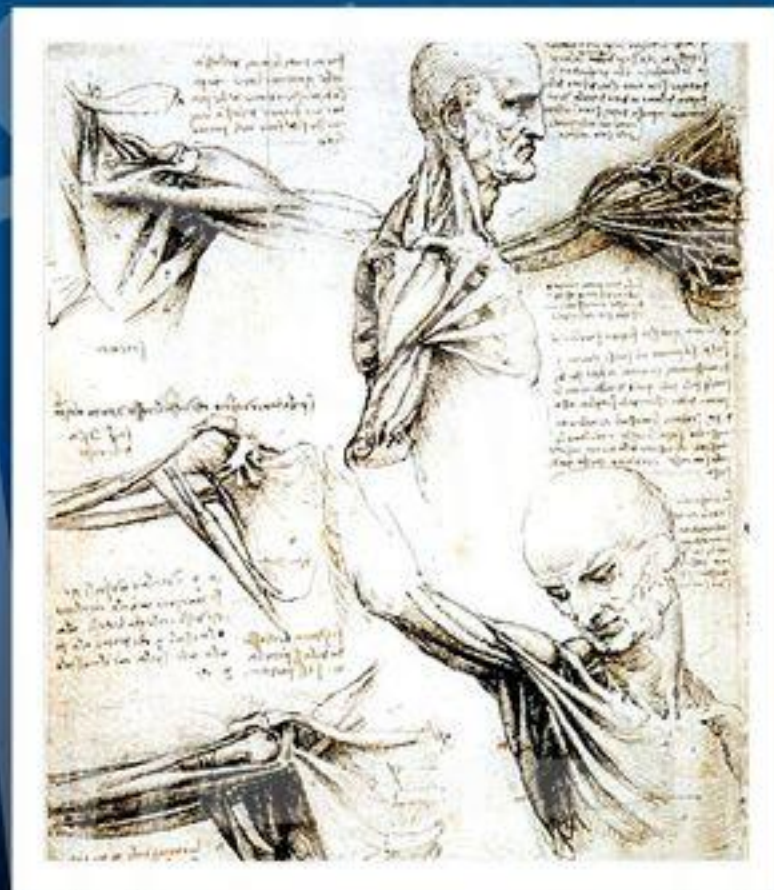

DR. ALEXANDRE FORTES



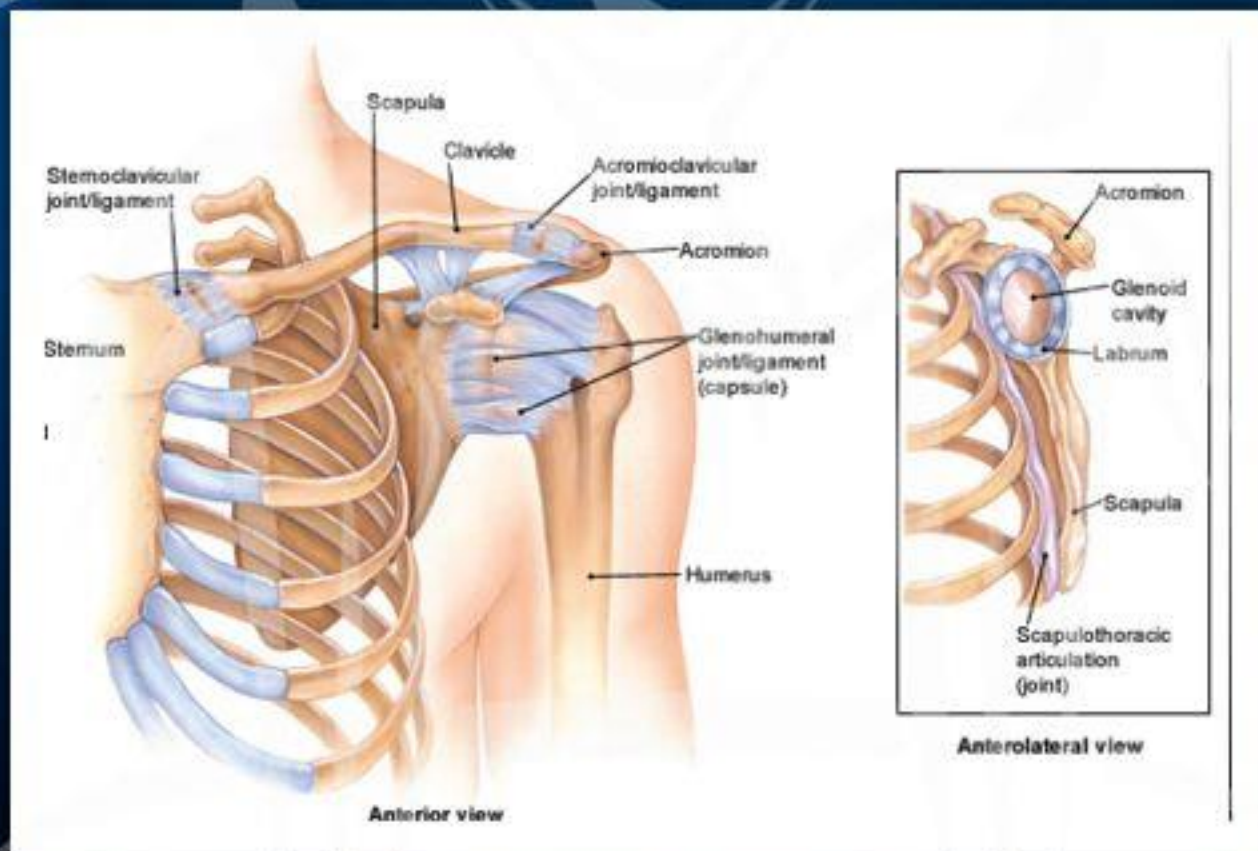
DOR NO OMBRO

ANATOMIA



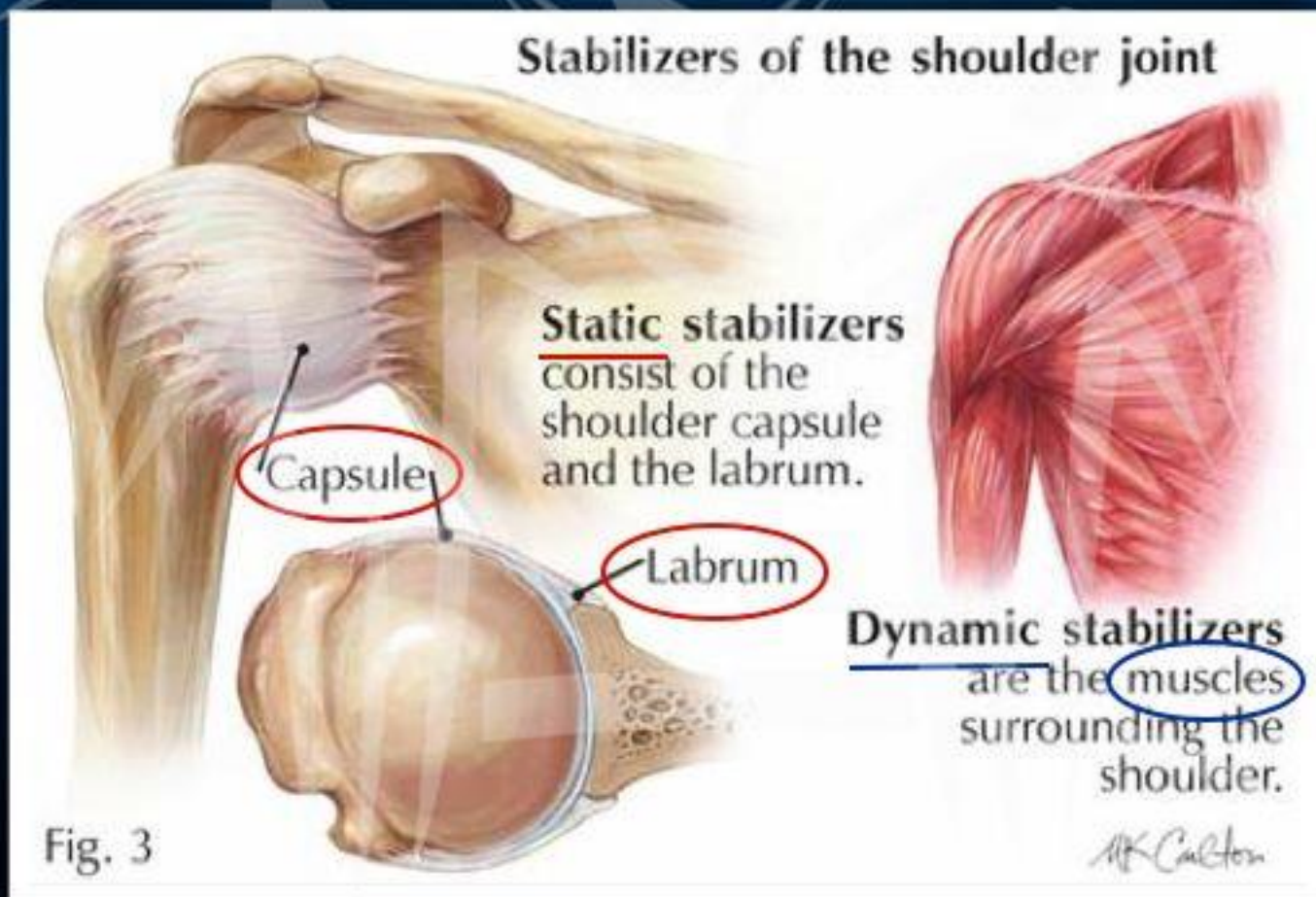
DOR NO OMBRO

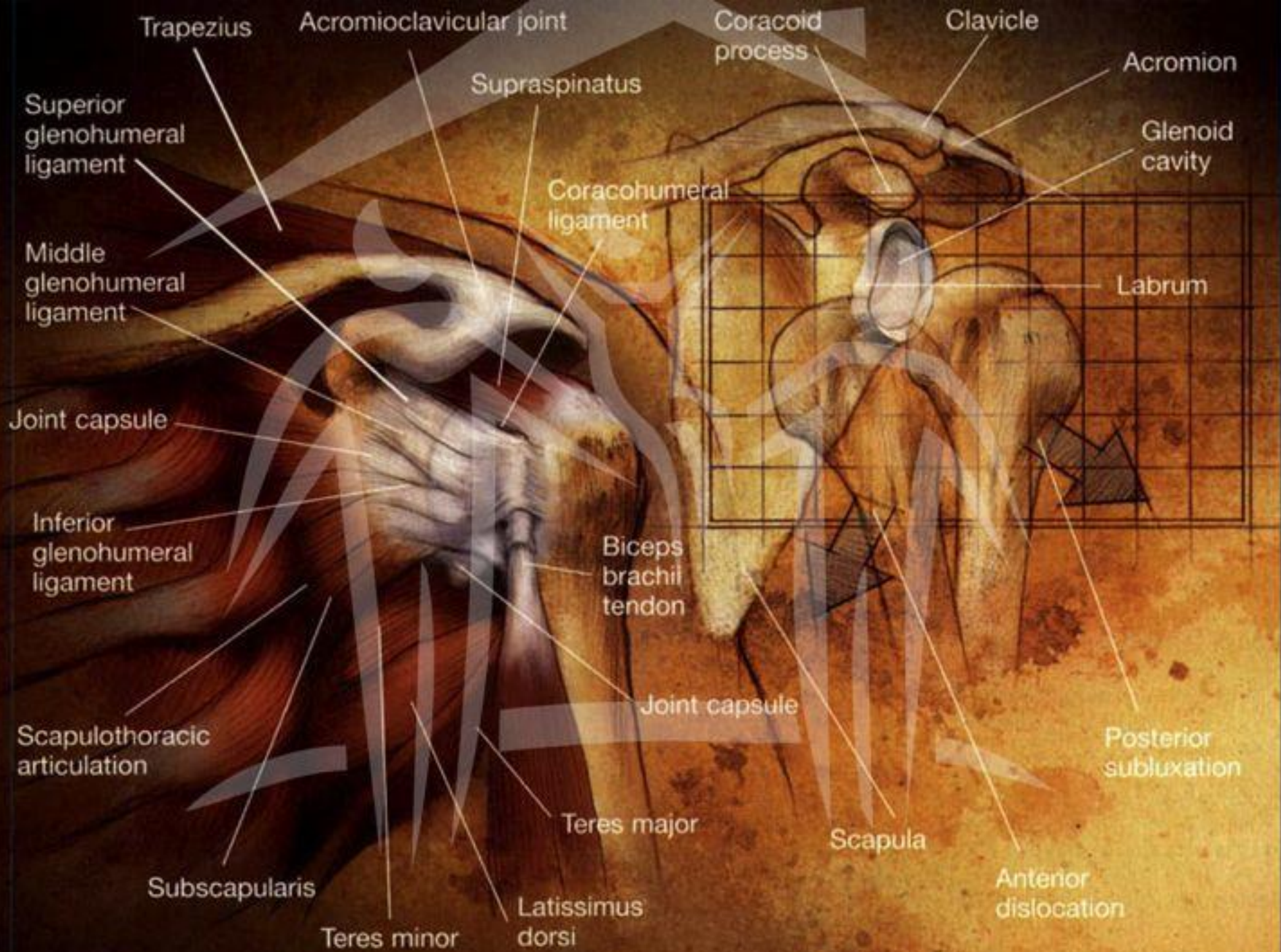
ANATOMIA



DOR NO OMBRO

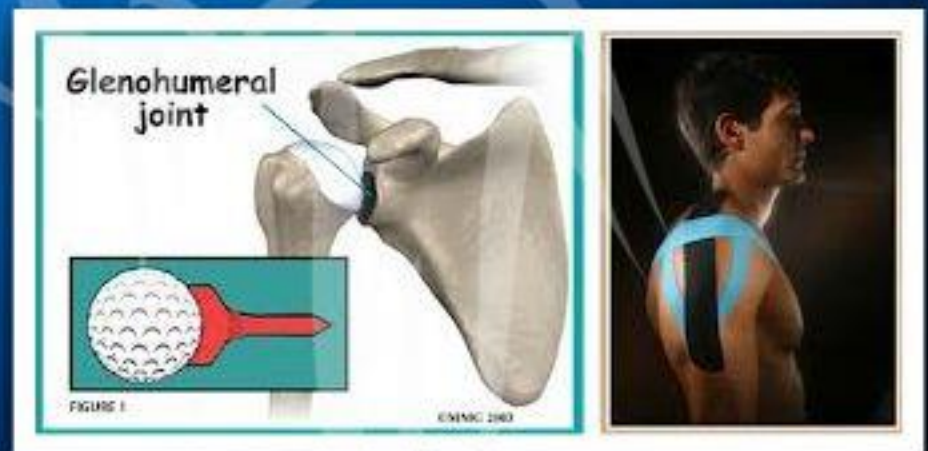
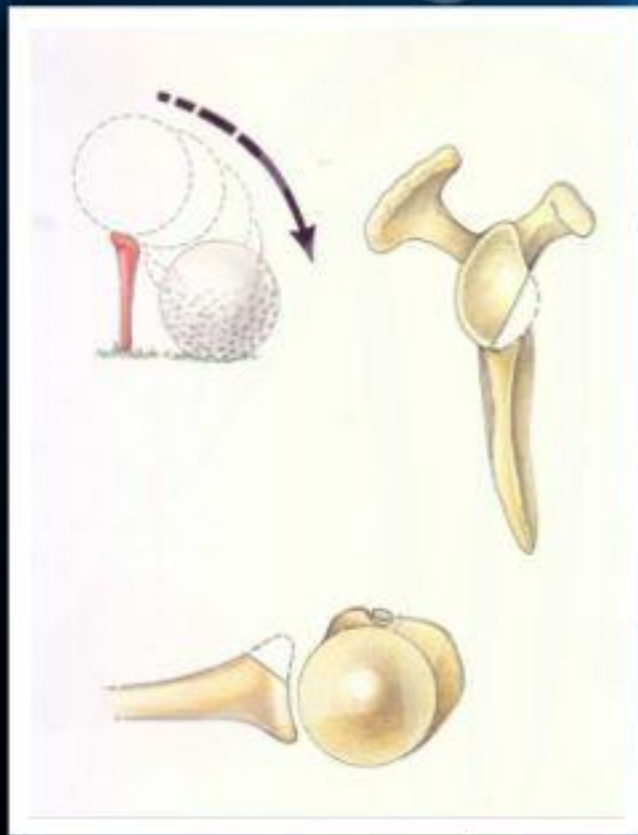
ESTABILIDADE





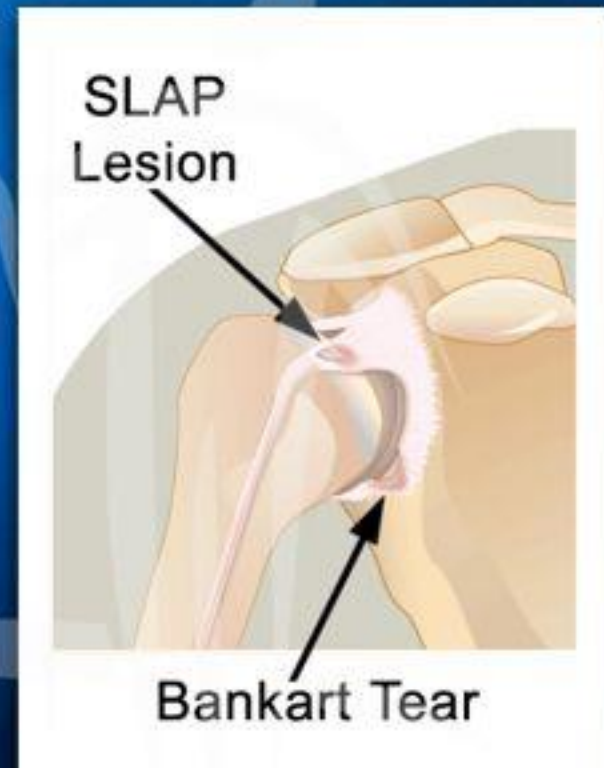
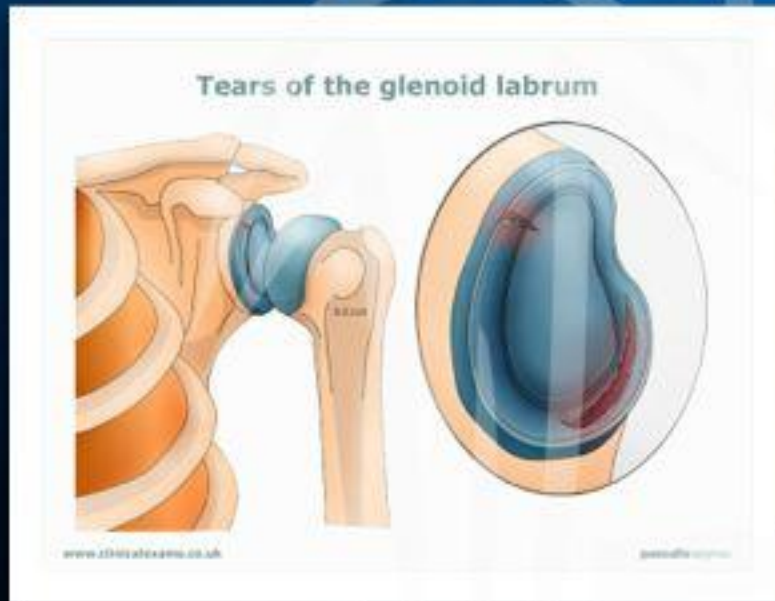ESTABILIDADE ESTÁTICA

ARTICULAÇÃO GLENOUMERAL



ESTABILIDADE ESTÁTICA

LABRUM

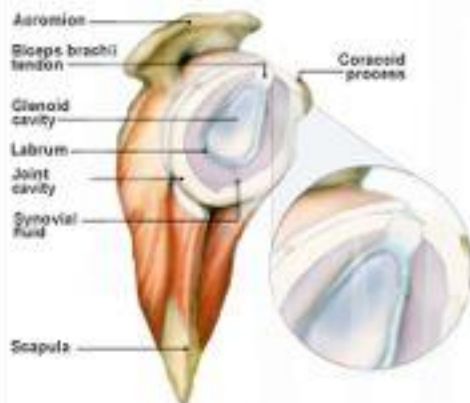


BANKART TEAR

ESTABILIDADE ESTÁTICA

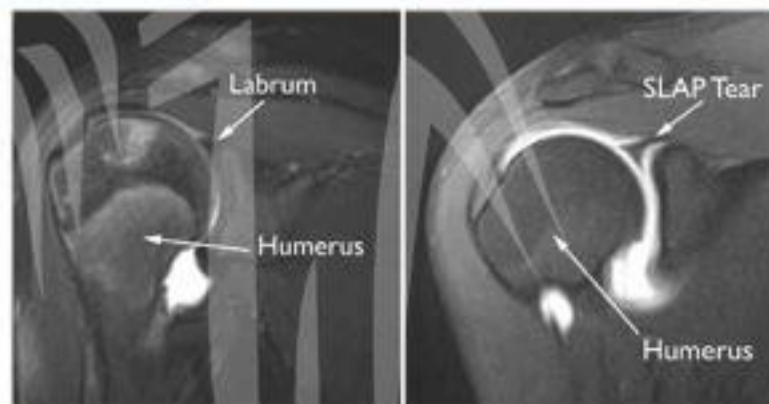LESÕES DO LABRUM

The Superior Labrum of the Shoulder Joint



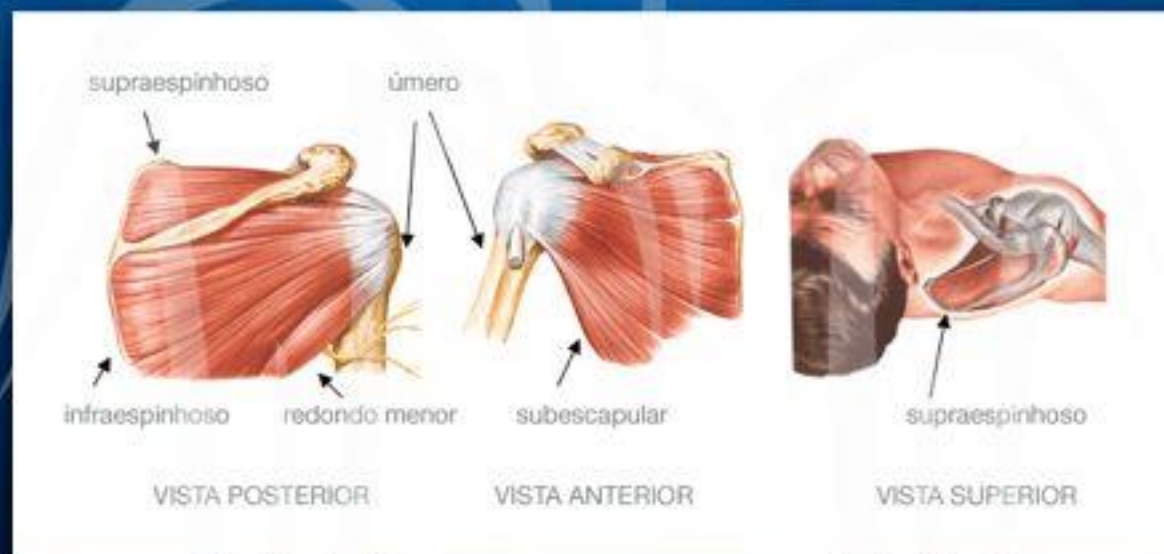Superior Labrum from Anterior to Posterior (SLAP) tears occur in the superior labrum at the top of the glenohumeral joint.

MedMorph.com



ESTABILIDADE DINÂMICA

MANGUITO ROTADOR



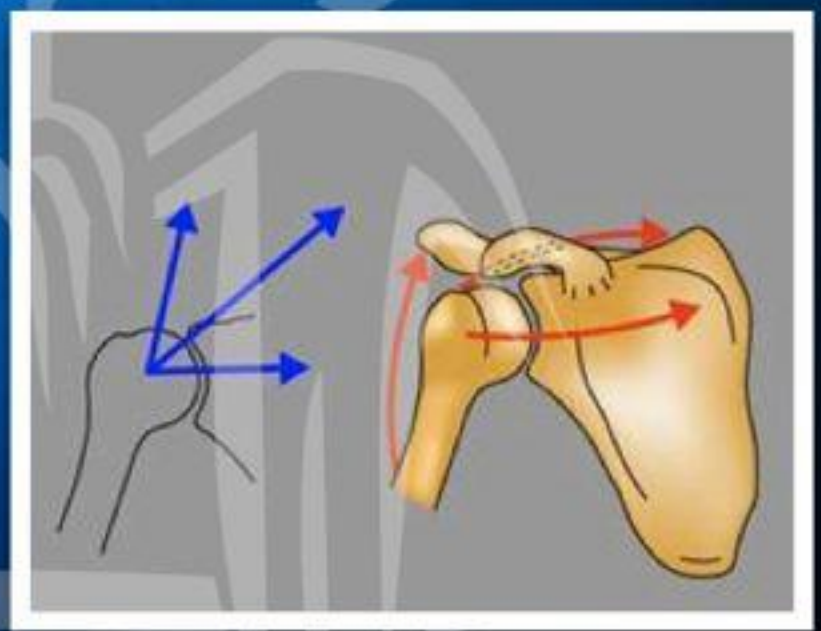
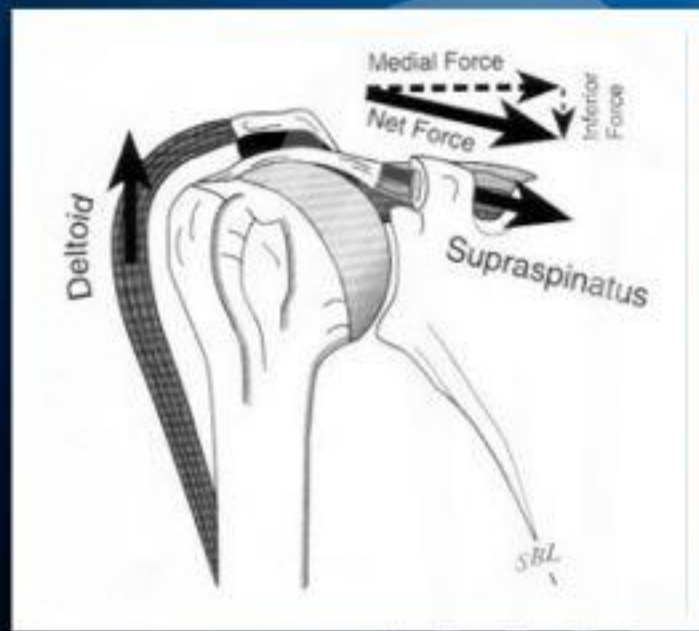
ARRETOUR

ARRETOUR

ARRETOUR

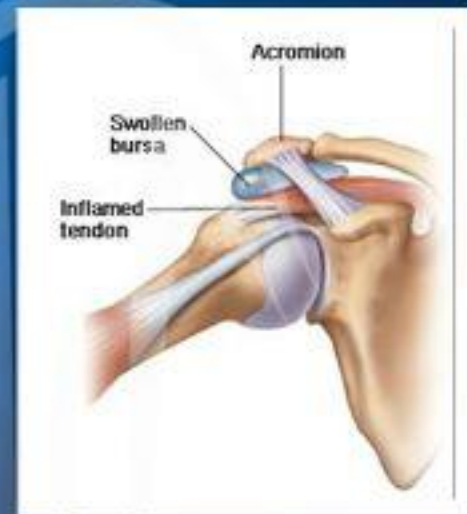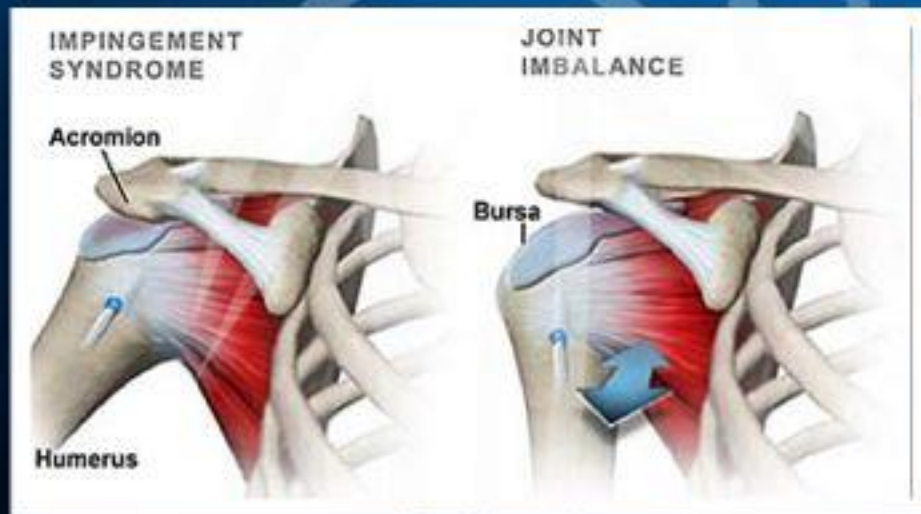
ESTABILIDADE DINÂMICA

MANGUITO ROTADOR VS DELTÓIDE



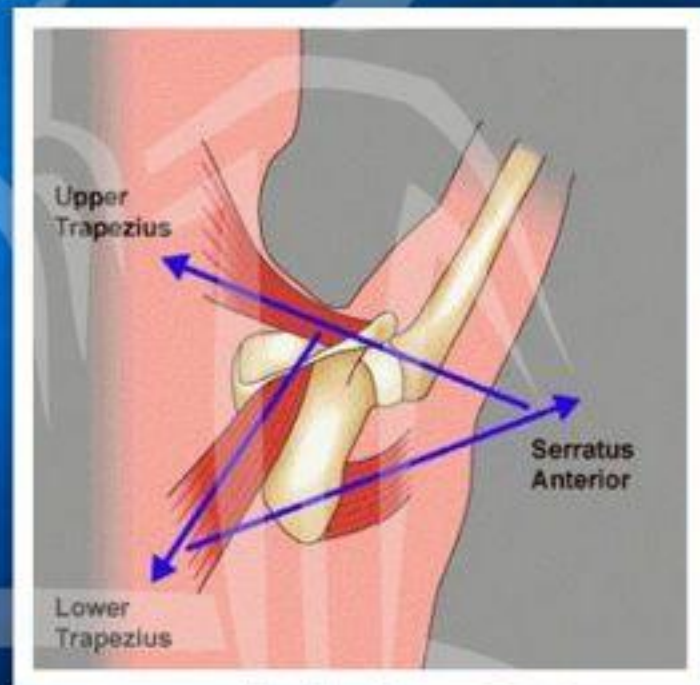
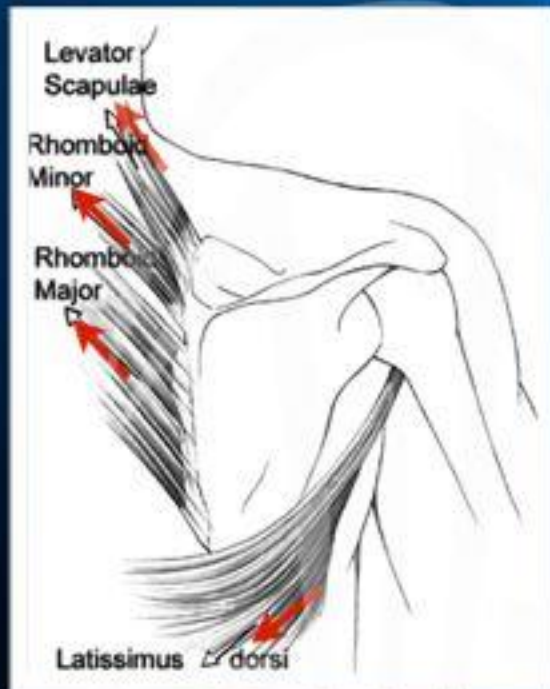
ESTABILIDADE DINÂMICA

MANGUITO ROTADOR VS DELTÓIDE

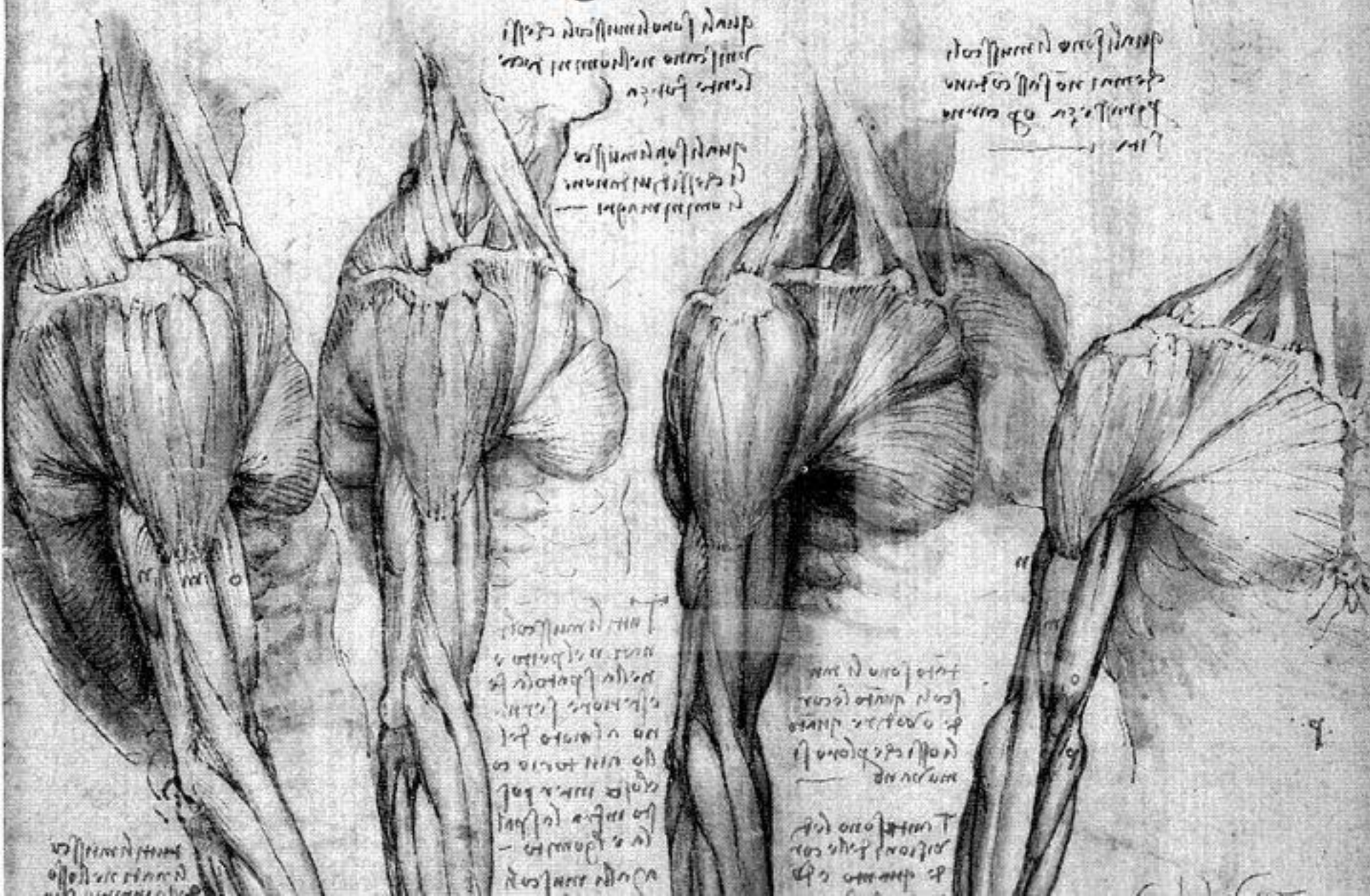


ESTABILIDADE DINÂMICA

ESTABILIZADORES DA ESCÁPULA



Semiologia do Ombro



SEMIOLOGIA

ABORDAGEM GERAL

- 1. Trauma?**
- 2. Causa intrínseca ou extrínseca ?**
- 3. História detalhada da dor**
- 4. Tratamentos prévios**

SEMIOLOGIA

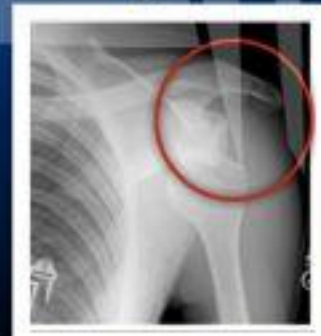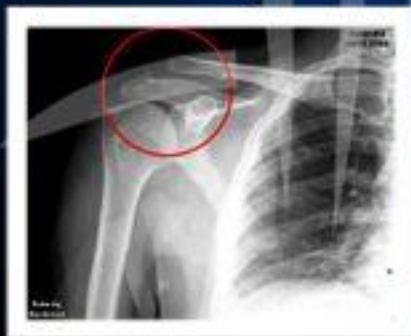TRAUMA

Fraturas do úmero e da clavícula são as mais frequentes

Fraturas da escápula são raras

Fraturas de clavícula são traumas de grande energia

Luxações acromioclavicular e glenoumeral são as mais frequentes



SEMIOLOGIA

INTRINSECA VS. EXTRINSECA

Dor de origem Intrínseca

- **Dor associada a movimentação da articulação**
- **Redução da amplitude de movimento**
- **Perda da força ou da função ou uma**
- **Instabilidade**

DOR NO OMBRO

EXTRINSECA

Cardiovascular

Isquemia miocárdica
Trombose da veia axilar
Sind. do desfiladeiro torácico

Torácica

Pneumonia de lobo superior
Tromboembolismo pulmonar
Tumor pulmonar de ápice

Abdominal

Doença hepatobiliar
Irritação diafragmática

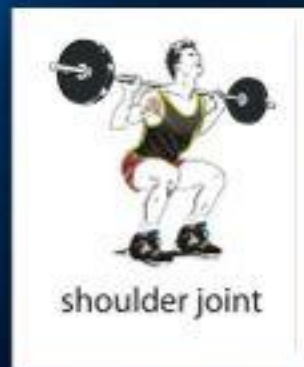
Neurológica

Radiculopatia
Herpes-zoster
Lesões do plexo braquial
Compressão do nervo supraespinhoso
Lesão raquimedular
Condições afetando as vertebra cervicais

SEMIOLOGIA

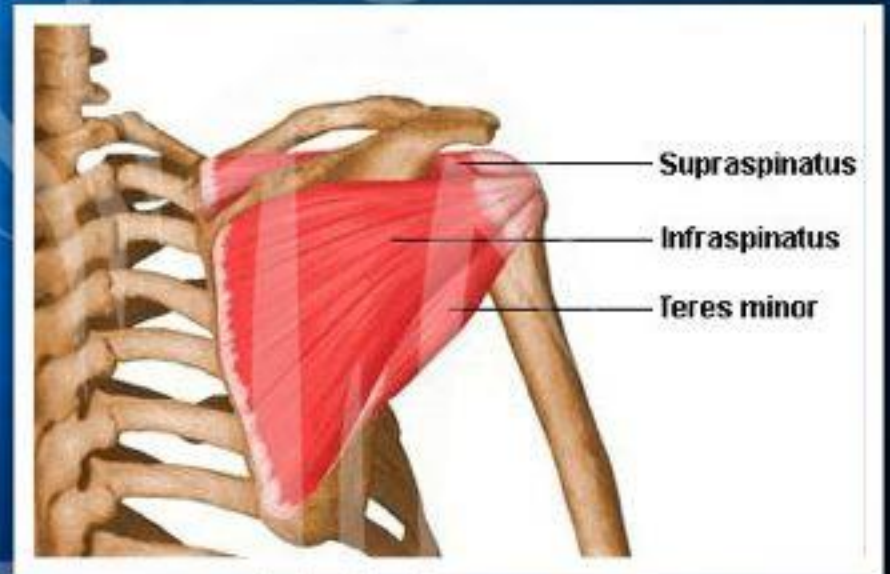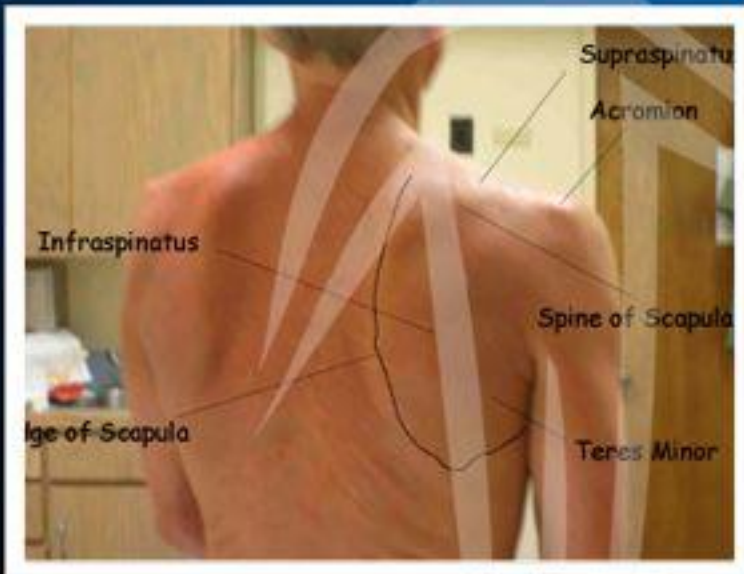
HISTÓRIA DA DOR

- Idade
- Mão dominante
- Esportes
- Atividades diárias
- Dor
- Instabilidade
- Rigidez
- Edema
- Amplitude de movimento
- Problema agudo ou crônico



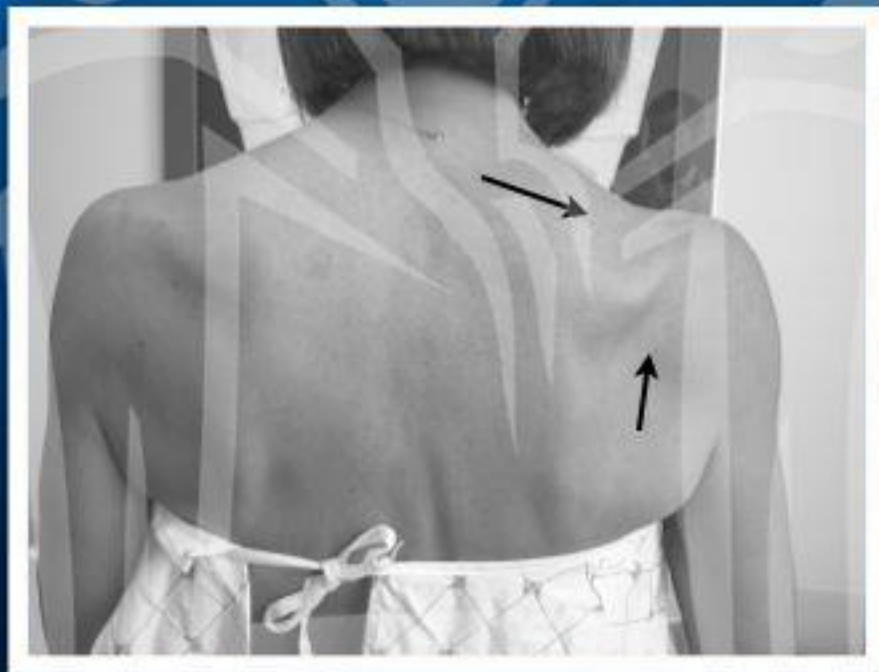INSPEÇÃO

TREINANDO O OLHAR



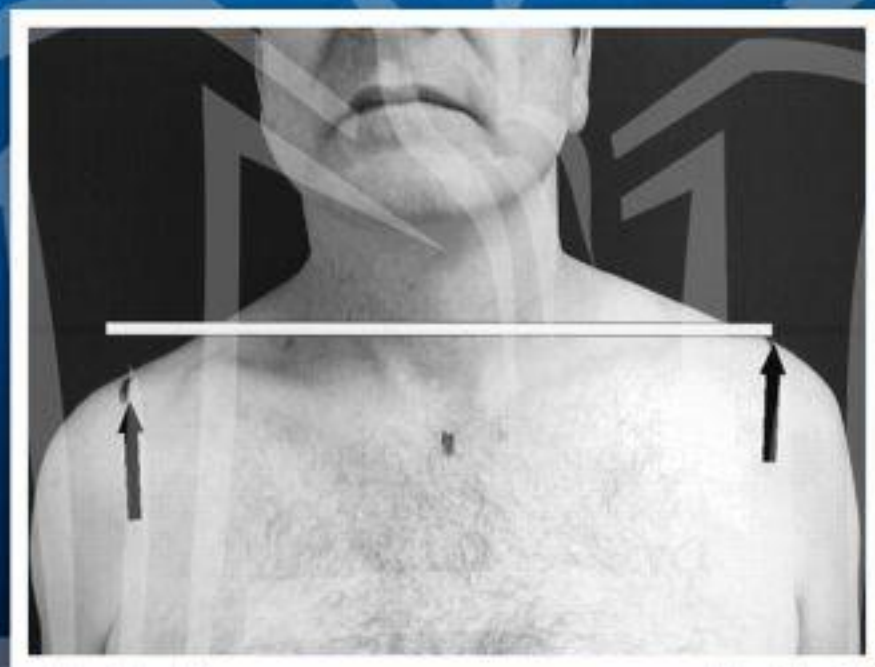
INSPEÇÃO

ATROFIA MUSCULAR



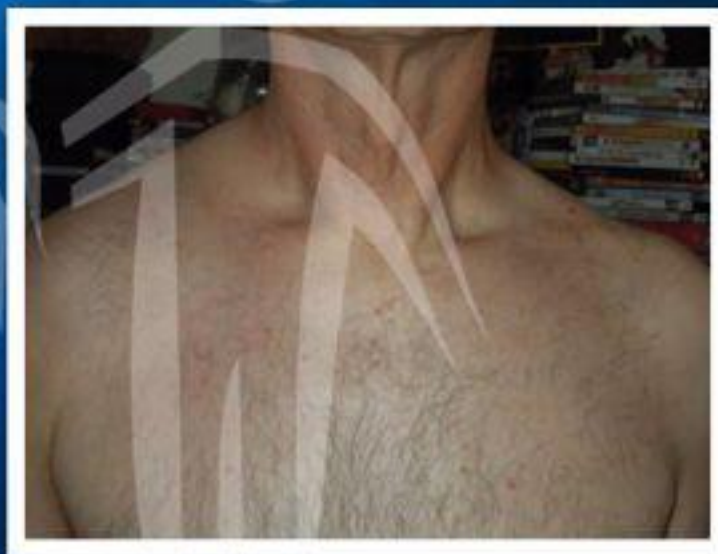
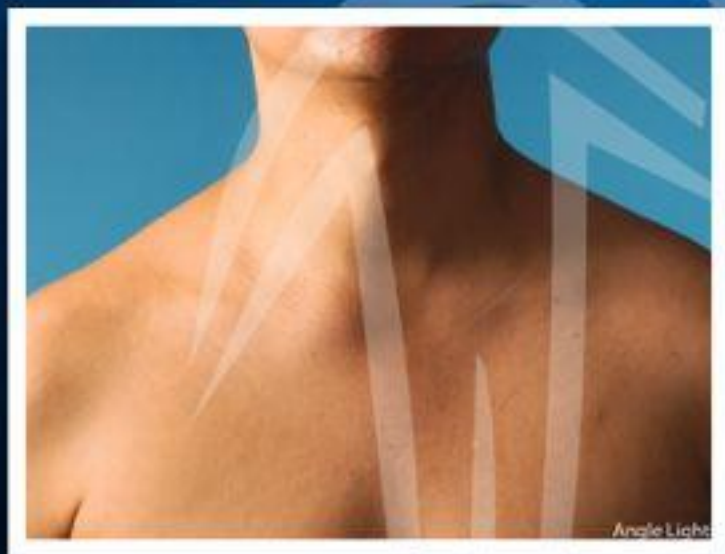INSPEÇÃO

ASSIMETRIA



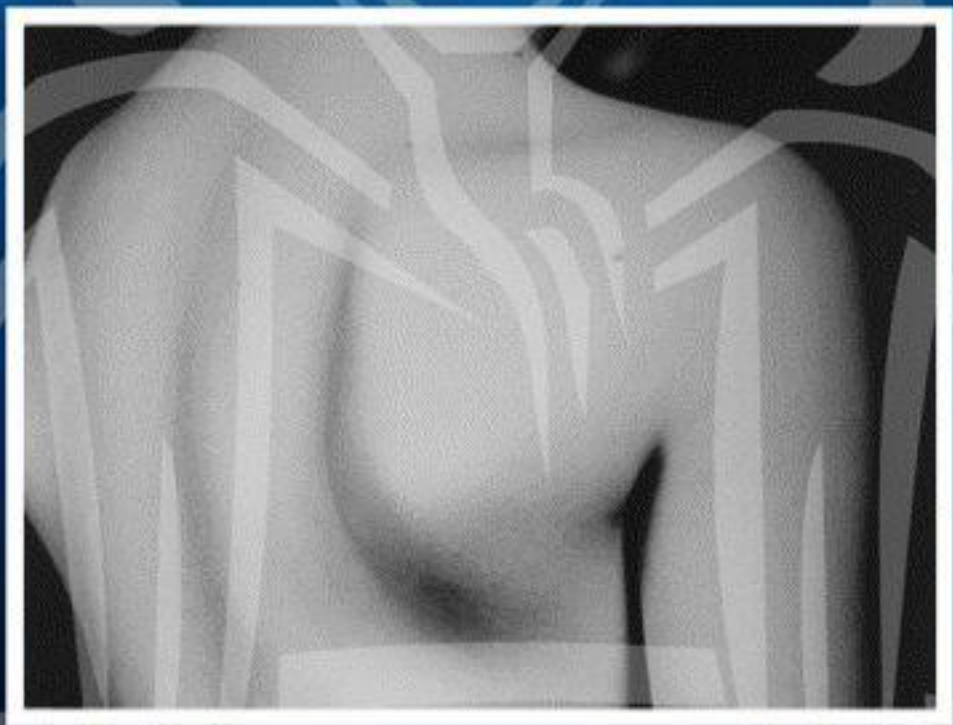INSPEÇÃO

ASSIMETRIA



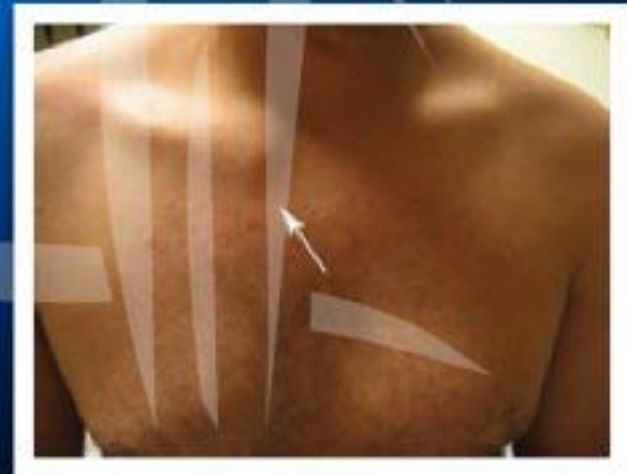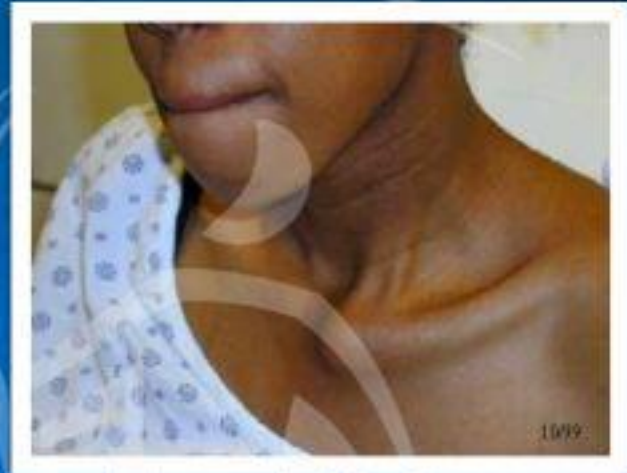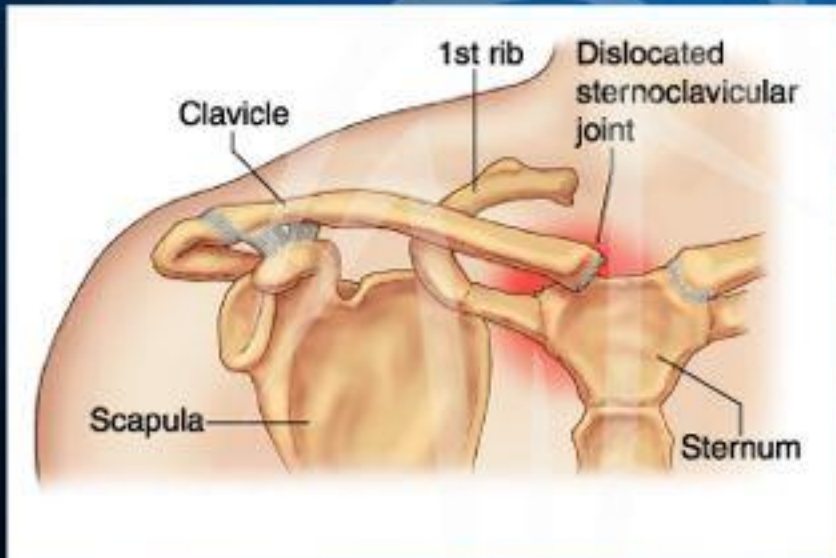
INSPEÇÃO

ESCÁPULA ALADA



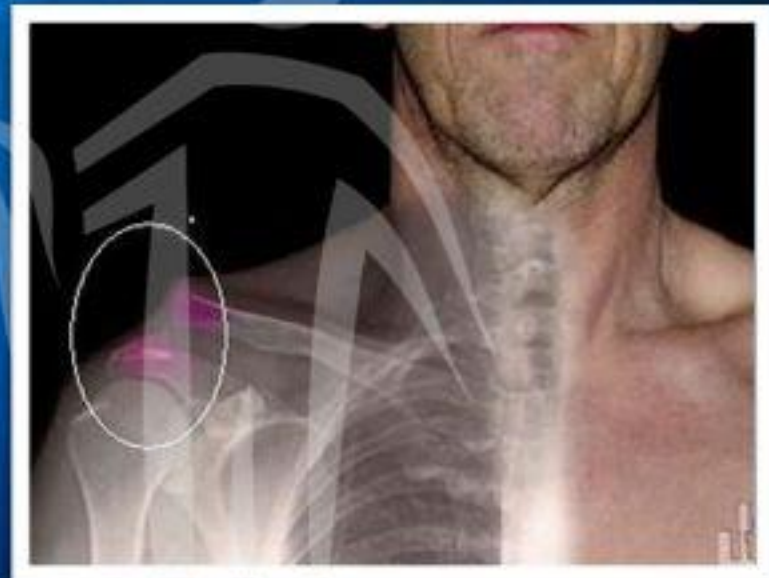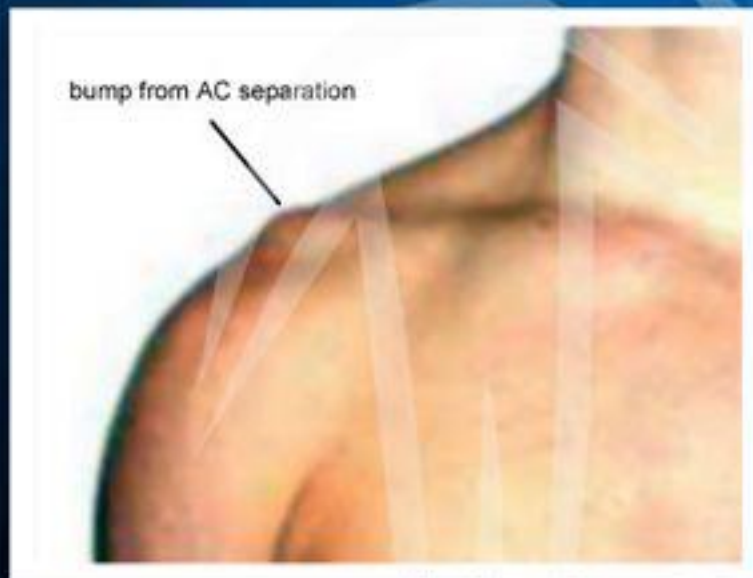
INSPEÇÃO

ART. ESTERNO-CLAVICULAR



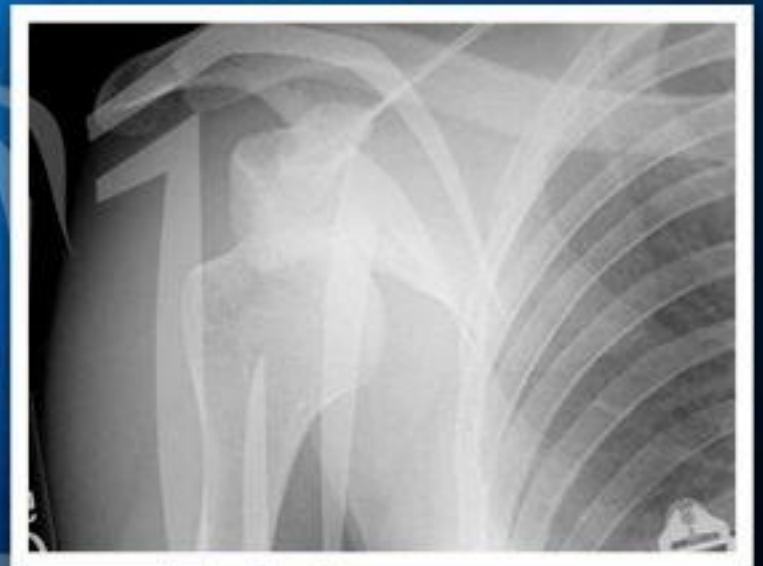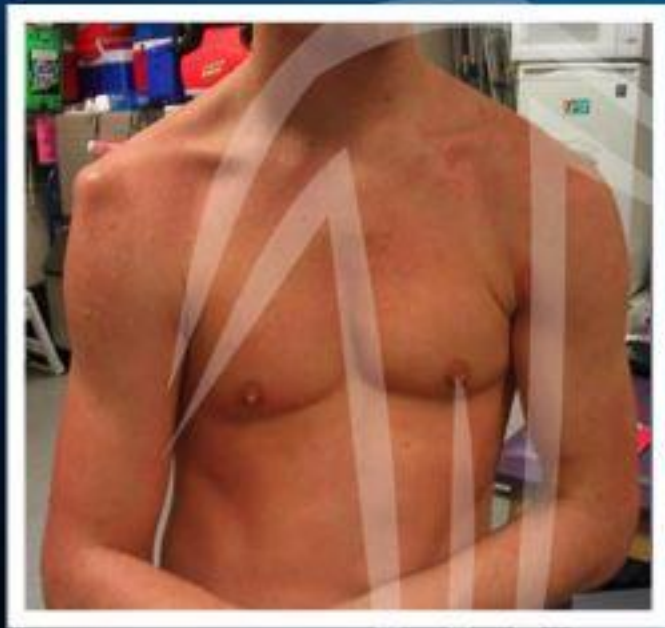INSPEÇÃO

LUXAÇÃO



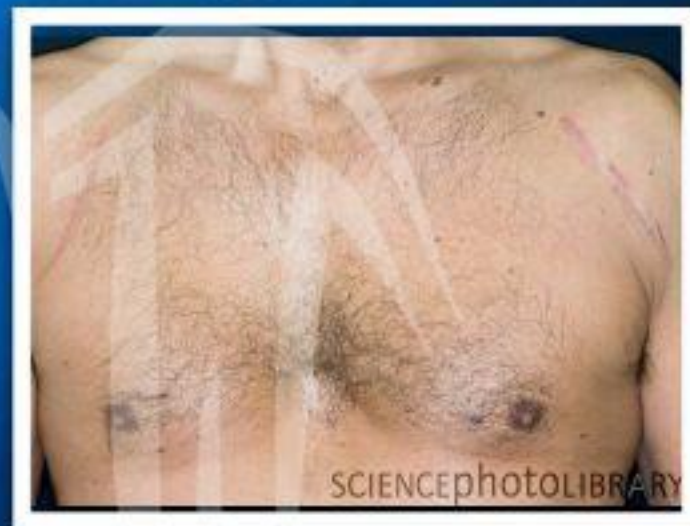
INSPEÇÃO

LUXAÇÃO



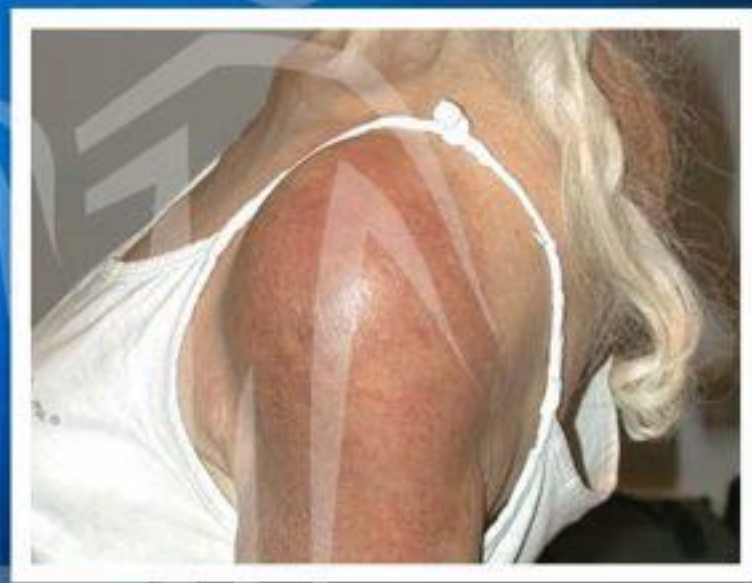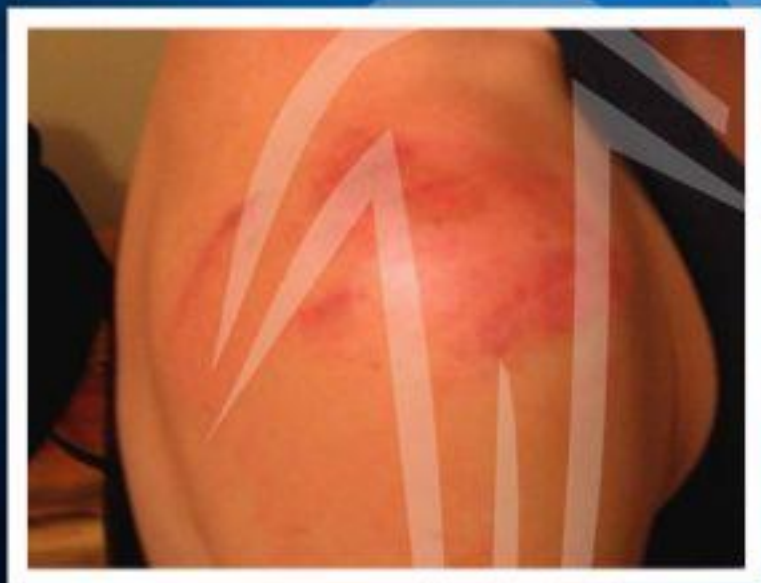INSPEÇÃO

CICATRIZES



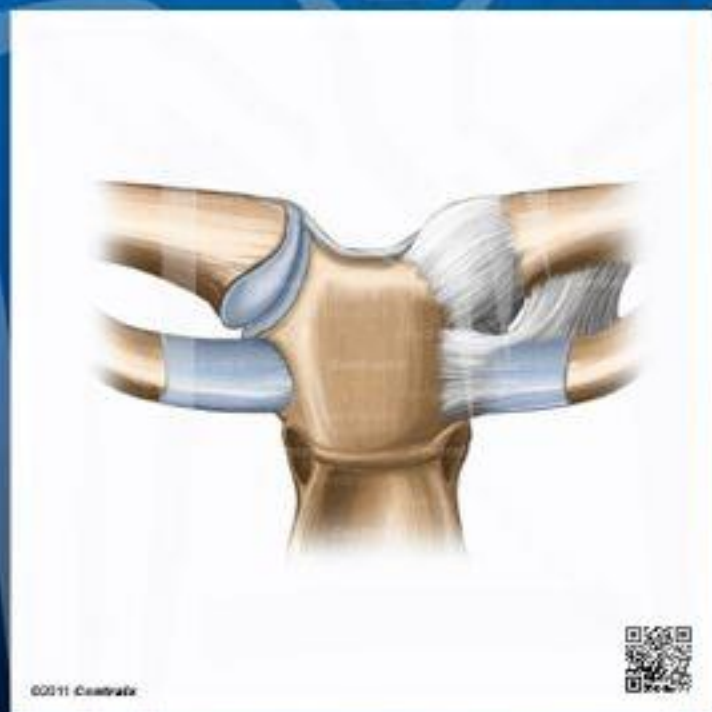
INSPEÇÃO

EQUIMOSSES



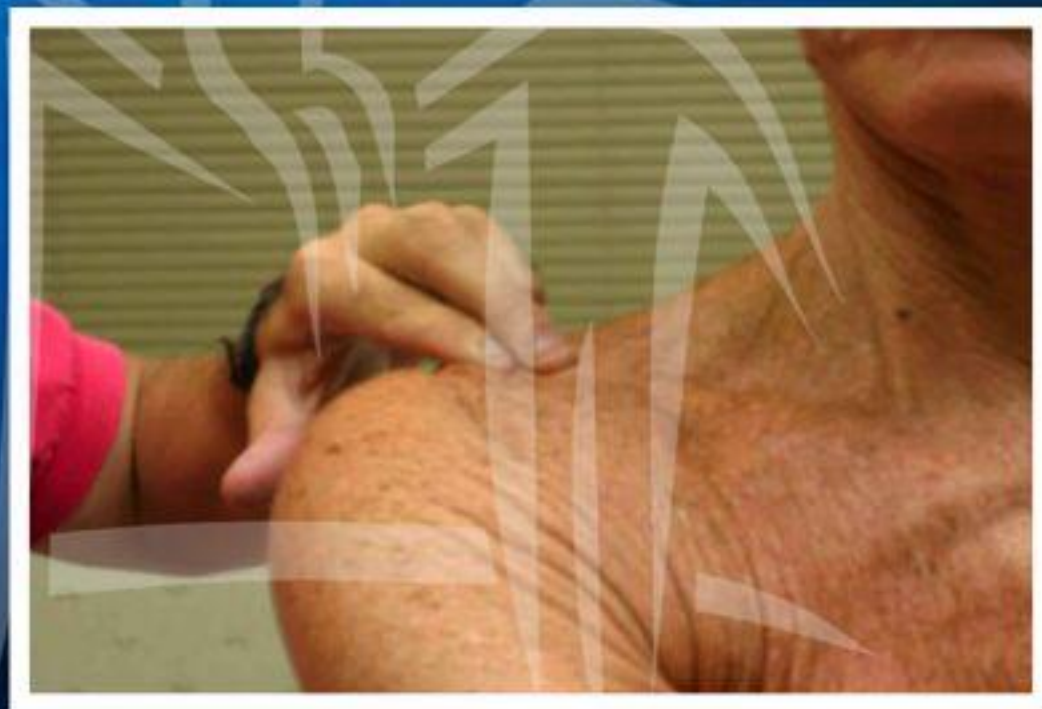
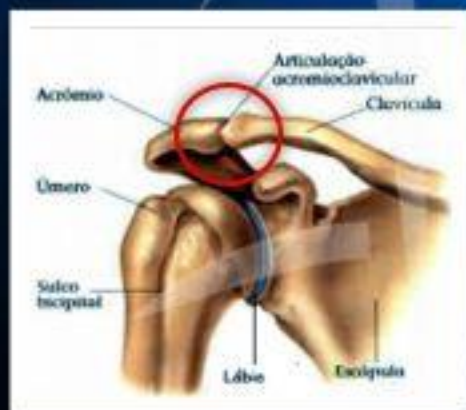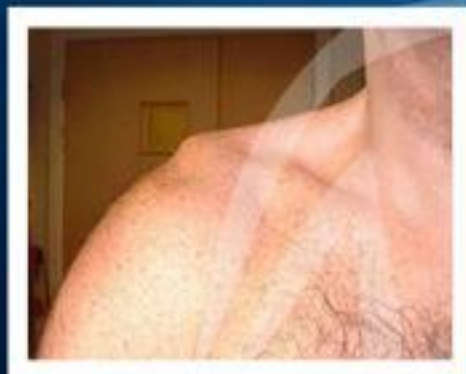PALPAÇÃO

ART. ESTERNO-CLAVICULAR



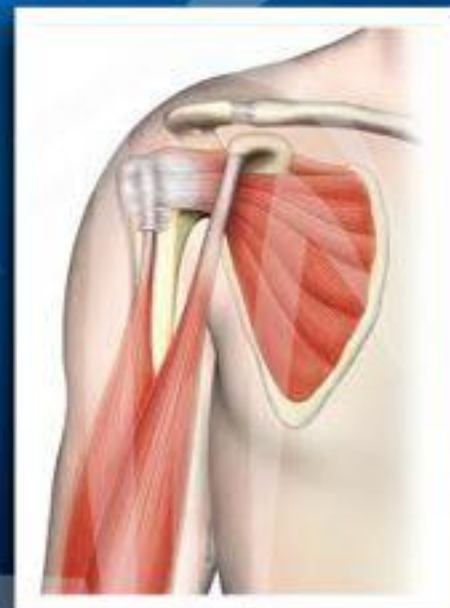
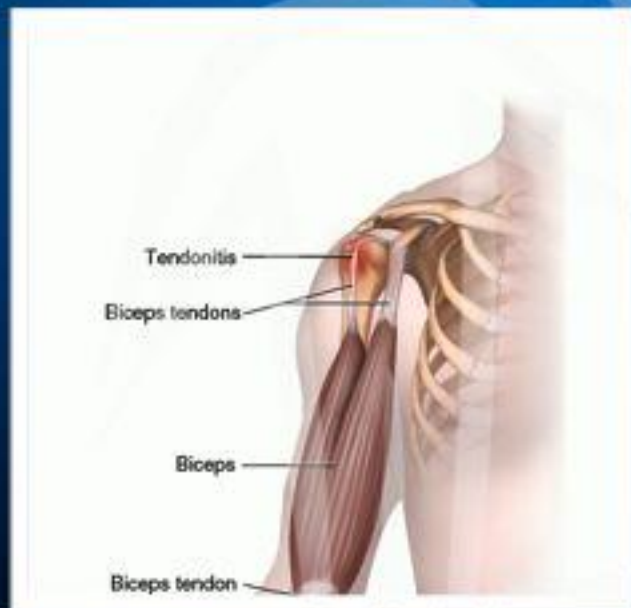
PALPAÇÃO

ART. ACROMIO-CLAVICULAR



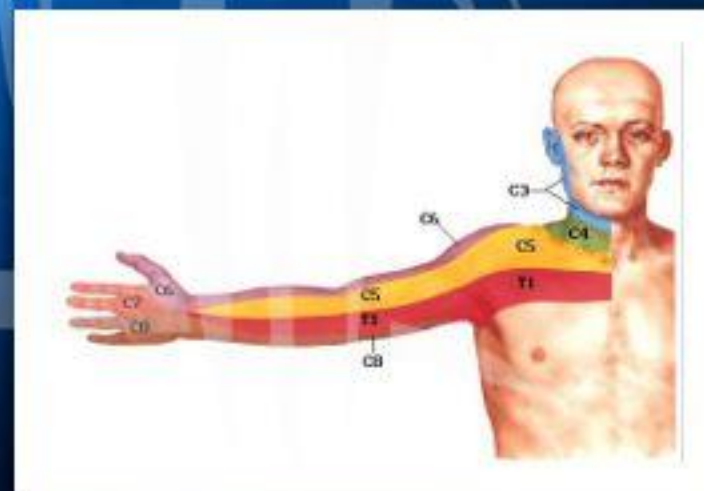
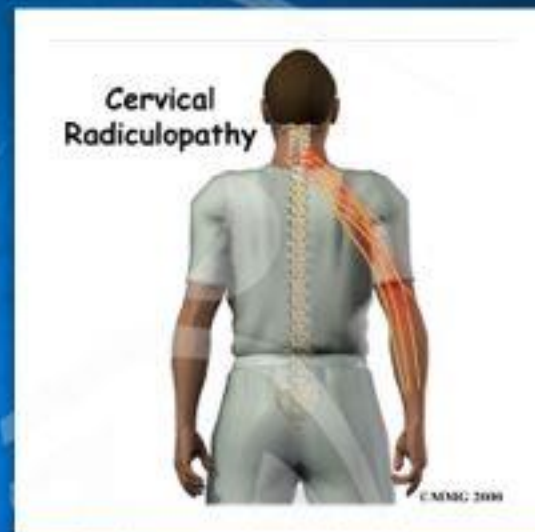
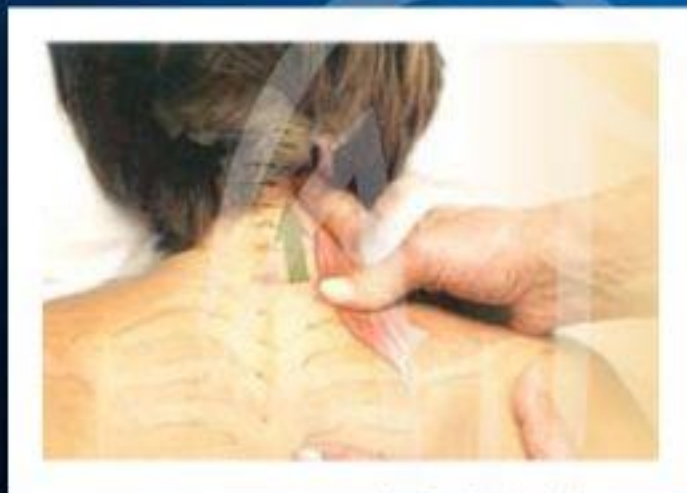
PALPAÇÃO

TENDÃO DO BÍCEPS



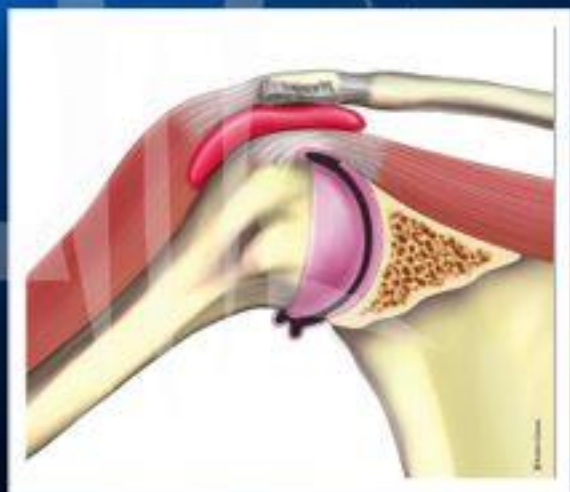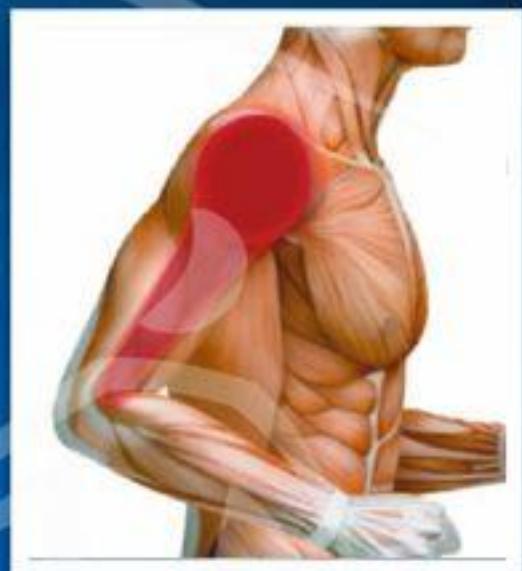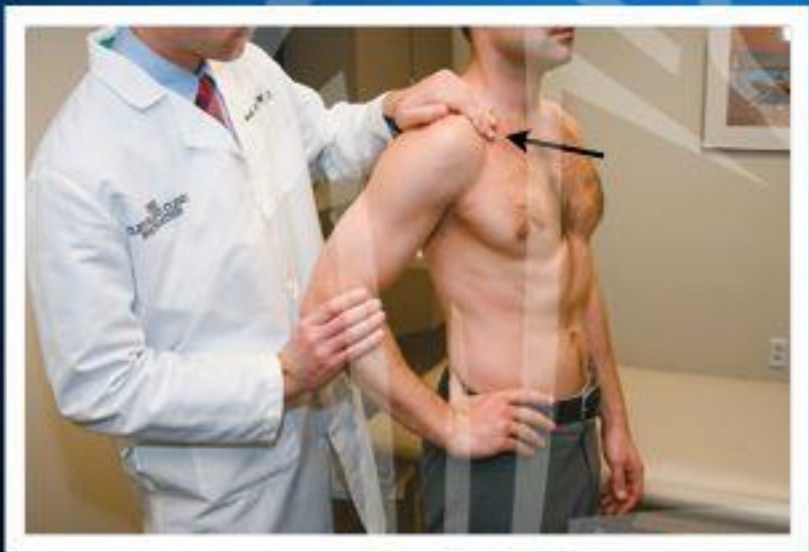
PALPAÇÃO

COLUNA CERVICAL



PALPAÇÃO

BURSAS



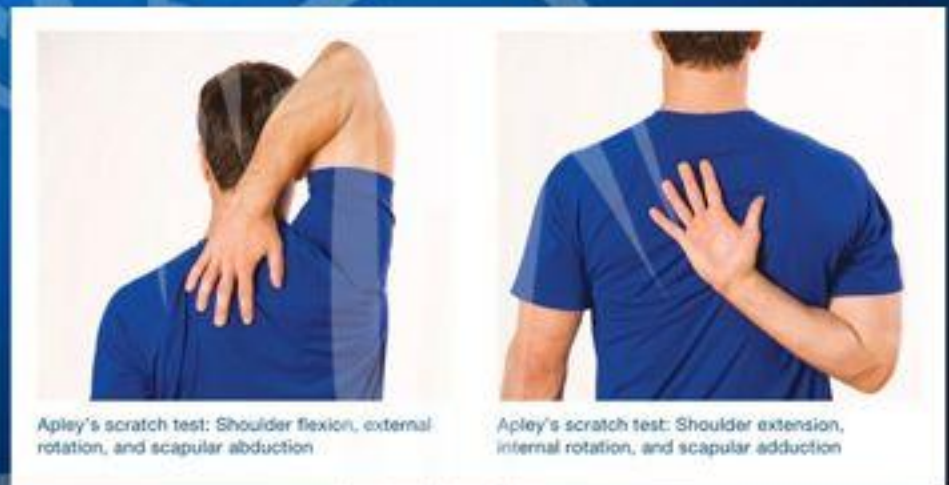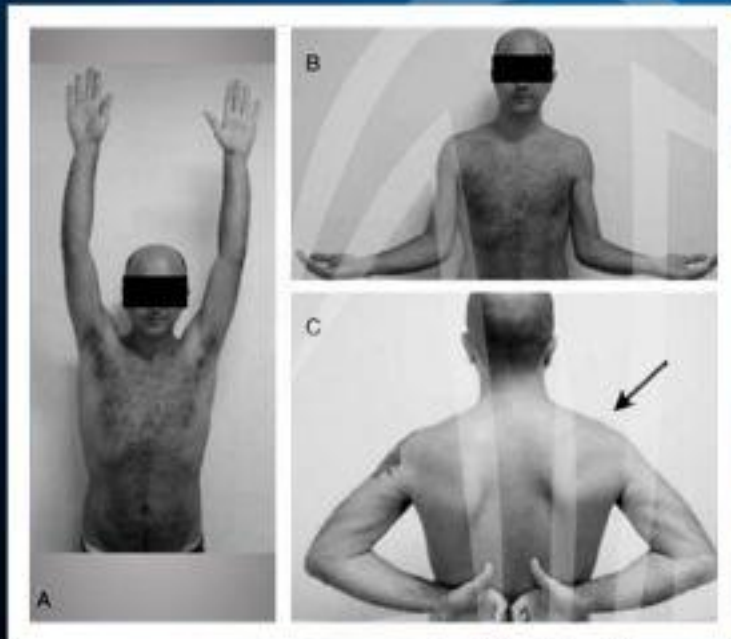SEMIOLOGIA

TESTES PROVOCATIVOS

- Appley
- Neer
- Hawkings
- Drop arm
- Cross arm
- Spurling
- Teste de Job
- Realocação
- Apreensão
- Sinal do Sulco
- Yergason (Biceps)
- Speeds test (Biceps)

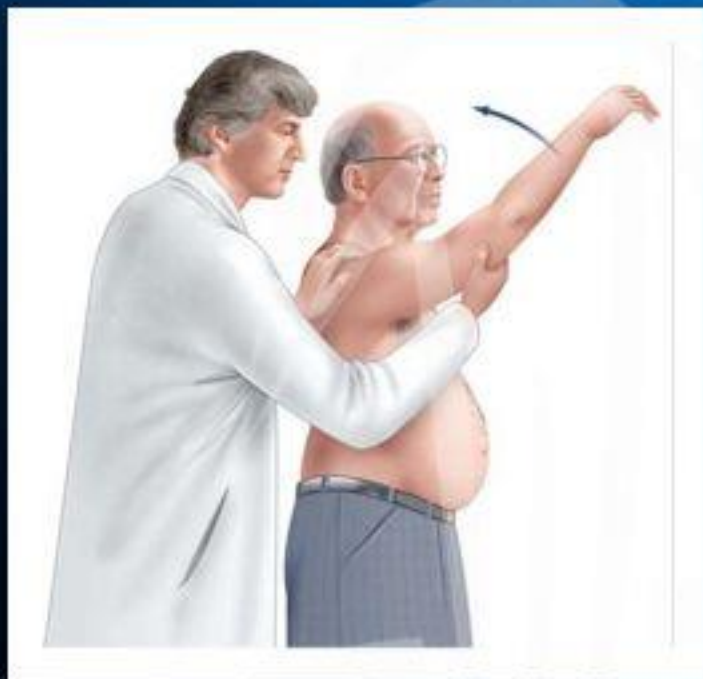
AMPLITUDE DE MOVIMENTO

TESTE DE APLEY



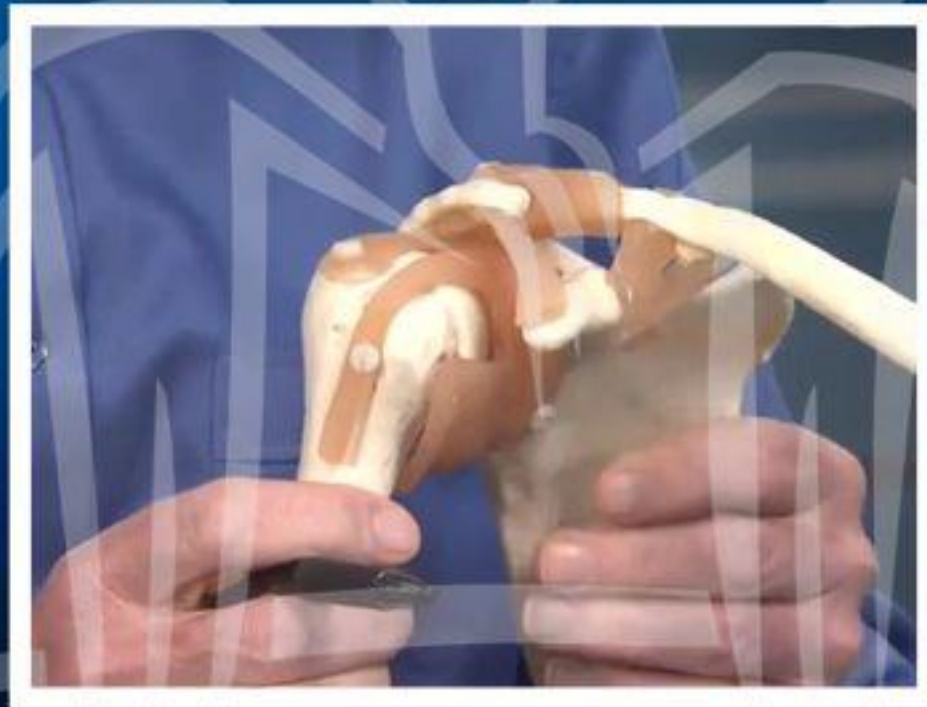SINDROME DO IMPACTO

TESTE DE NEER



SINDROME DO IMPACTO

IMPINGEMENT



SINDROME DO IMPACTO

IMPINGEMENT

**Rotator cuff
tendonitis**

Inflamed
tendon



**Shoulder
bursitis**

Inflamed
bursa and
tendon



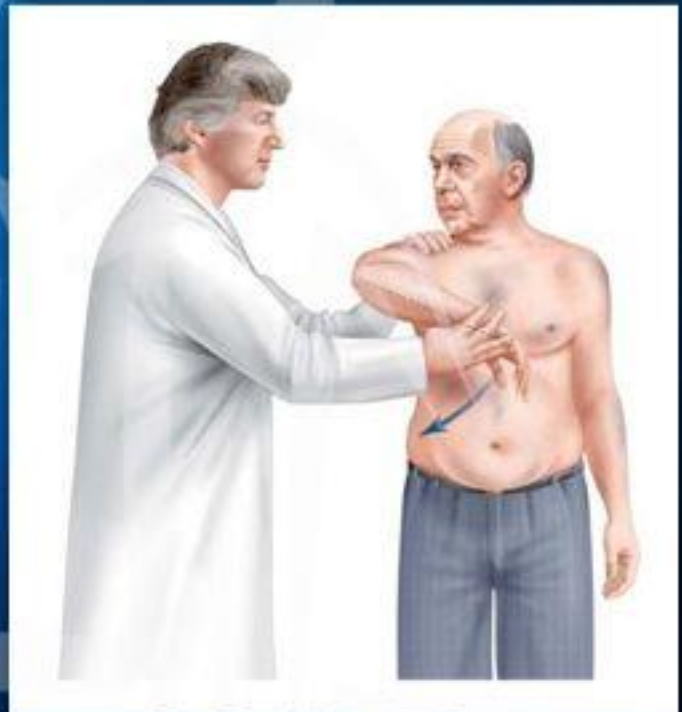
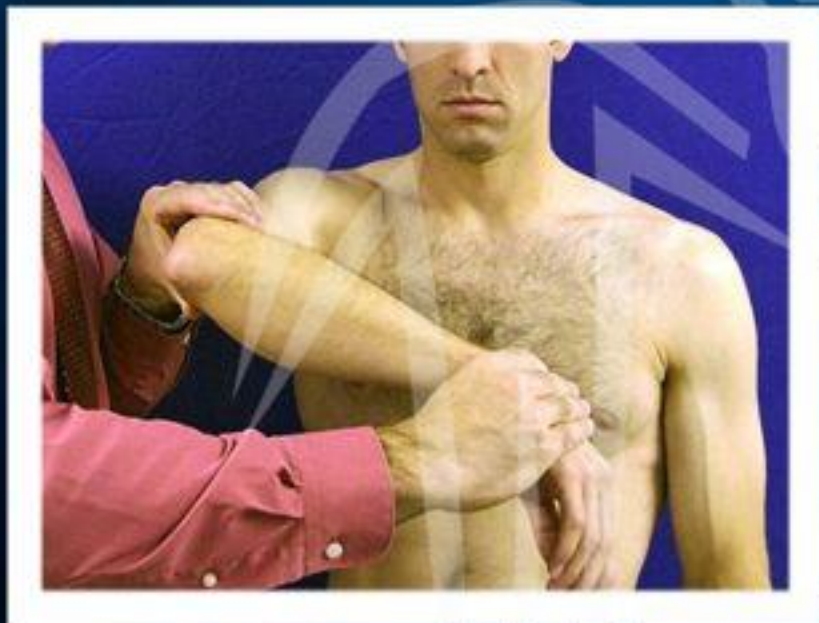**Rotator cuff
tear**

Tendon
tear



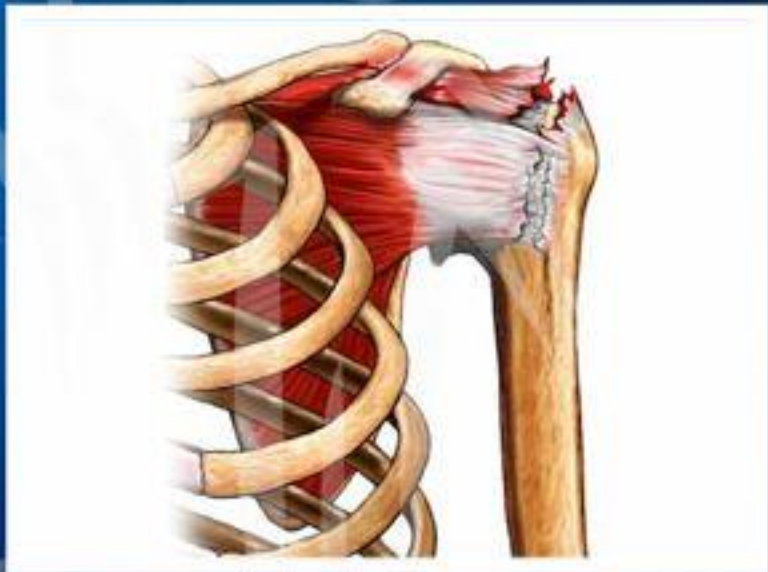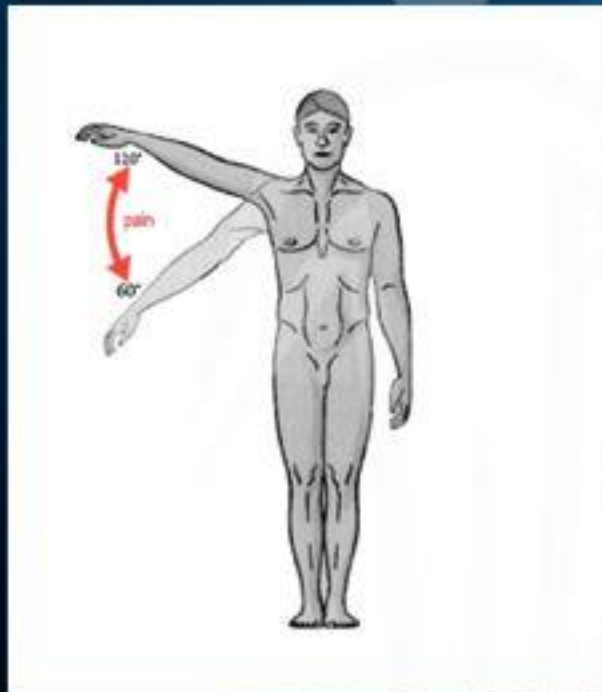
SINDROME DO IMPACTO

TESTE DE HAWKINS



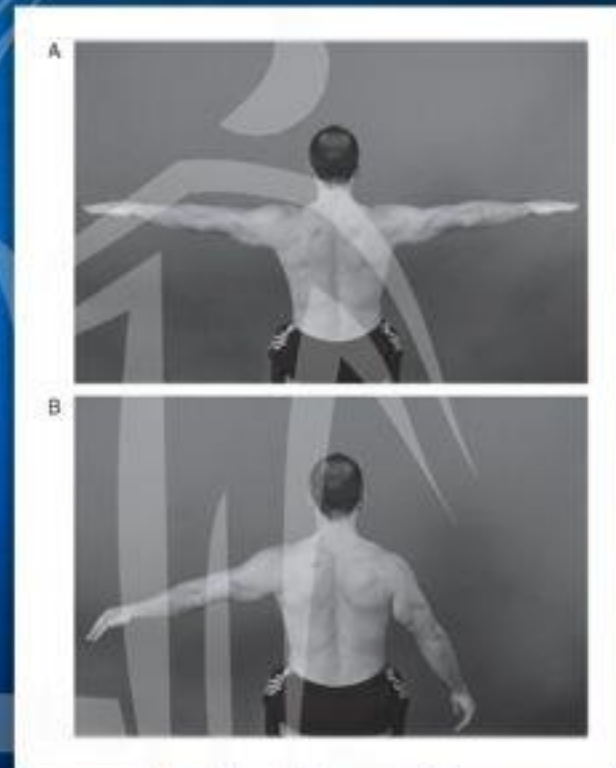
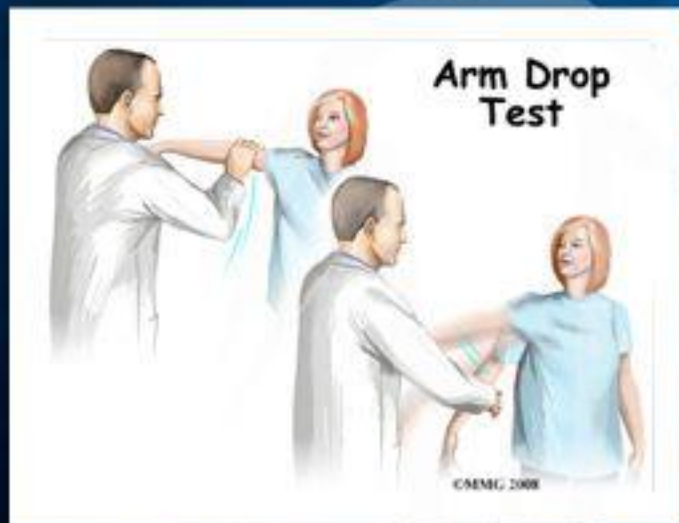
DROP ARM TEST

ROTURA DO SUPRAESPINHOSO



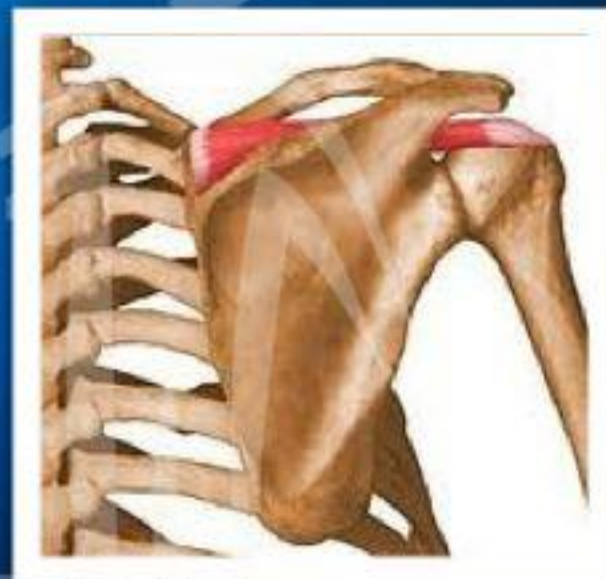DROP ARM TEST

ROTURA DO SUPRAESPINHOSO



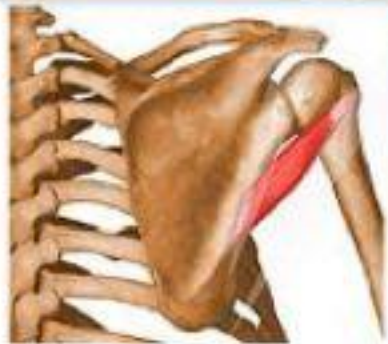TESTE DE JOB

SUPRA-ESPINHOSO

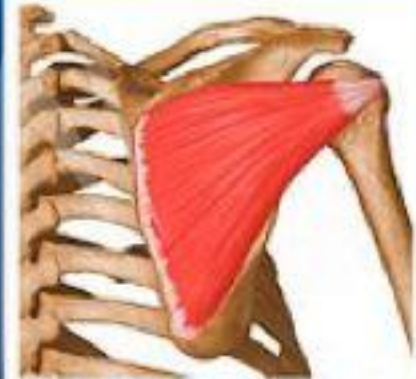
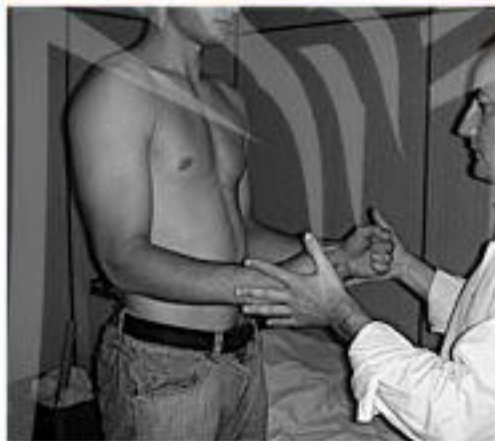
ROTAÇÃO EXTERNA

INFRA-ESPINHOSO E REDONDO MENOR



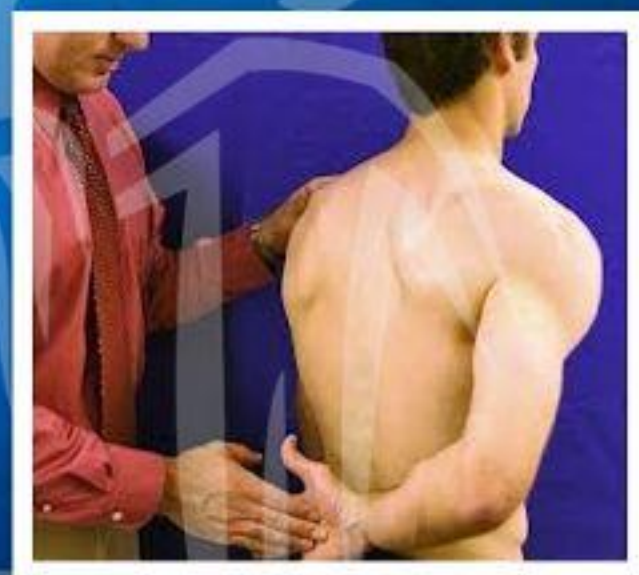
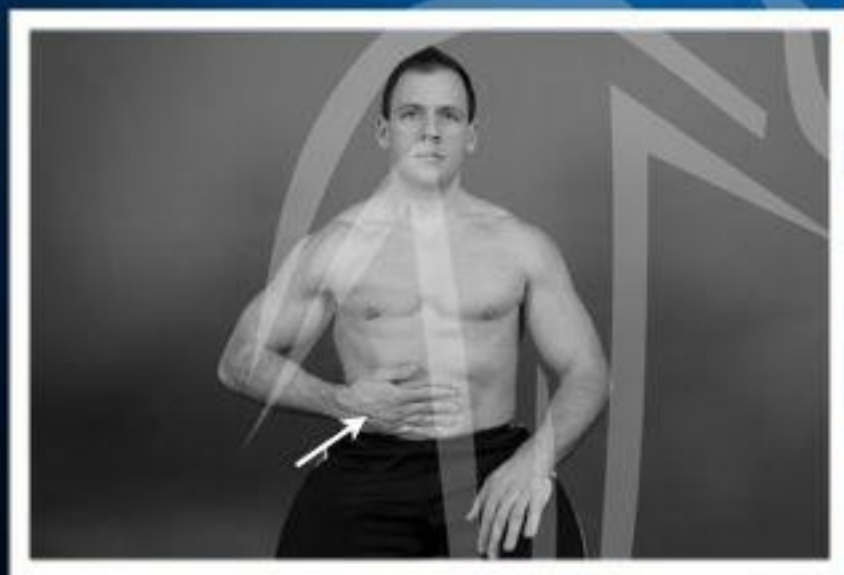
Redondo Menor



Infra-espinhal

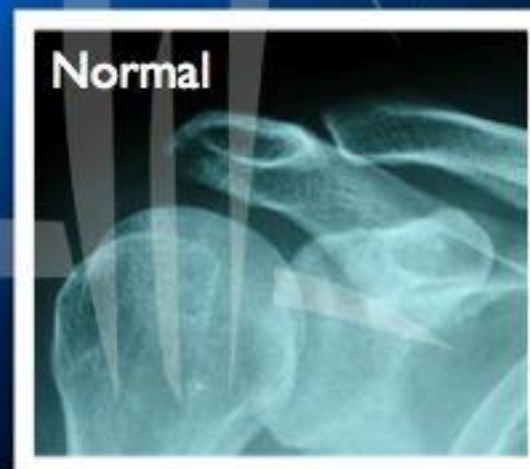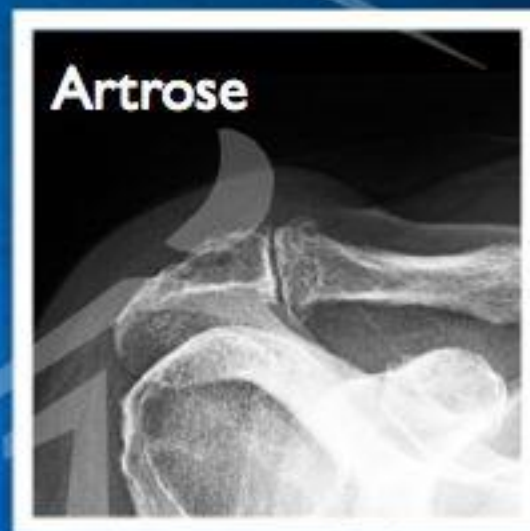
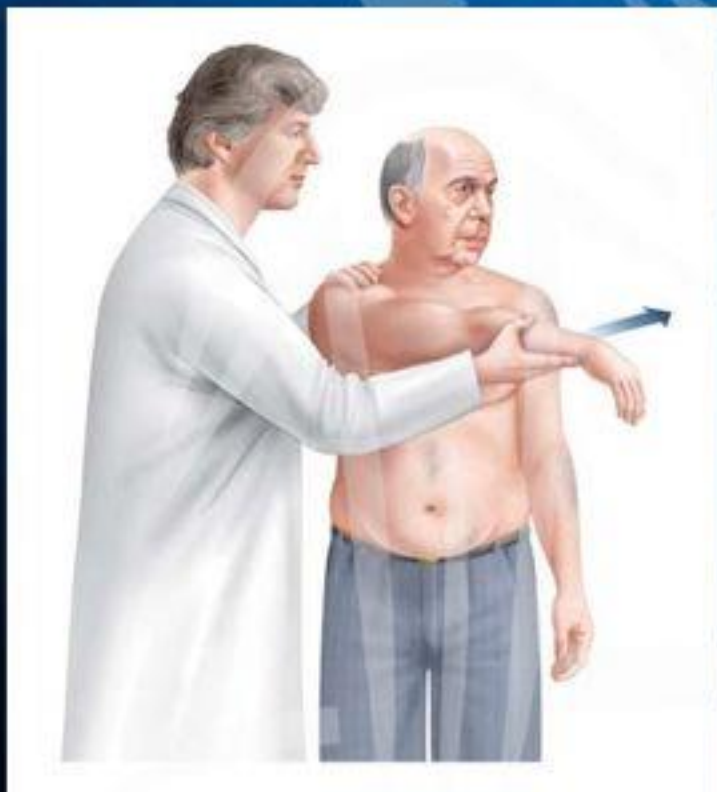
LIFT-OFF TEST / ROTAÇÃO INTERNA

SUBSCAPULAR



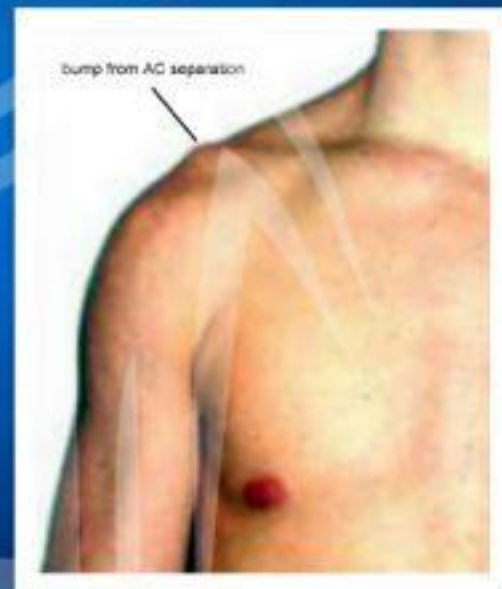
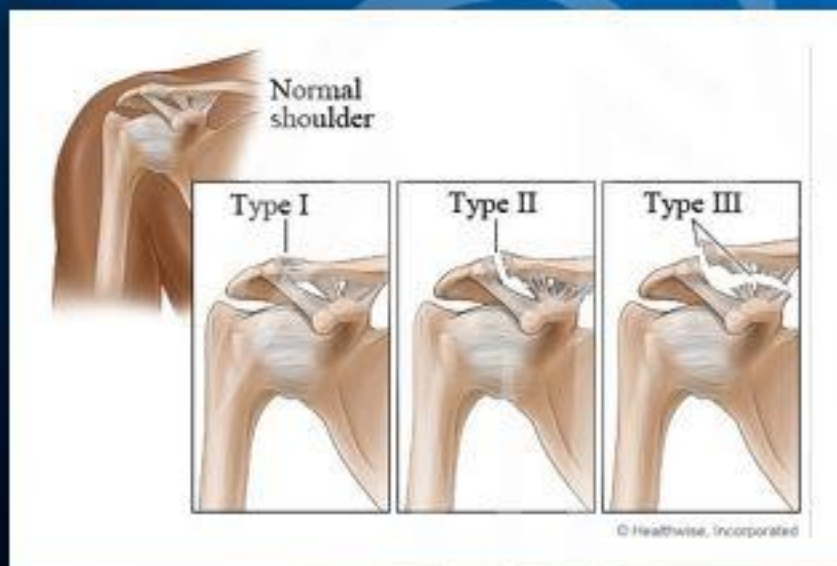
CROSS-ARM TEST

ARTROSE ACROMIO-CLAVICULAR



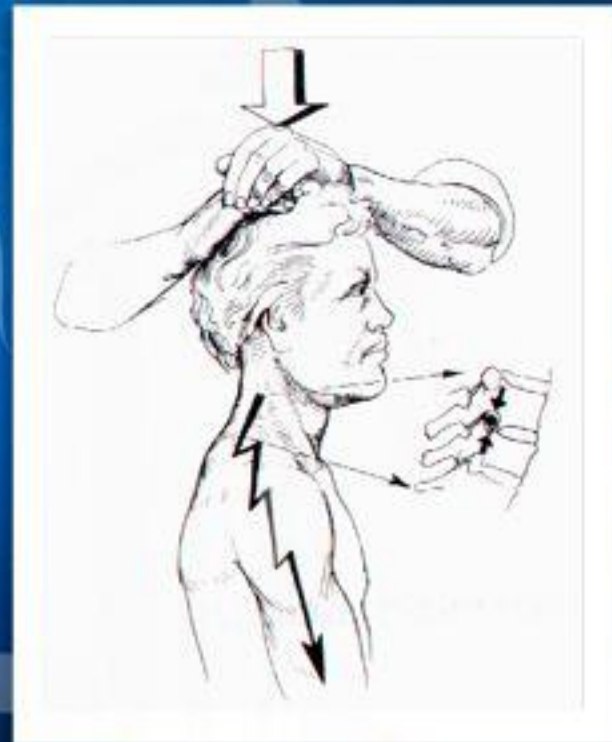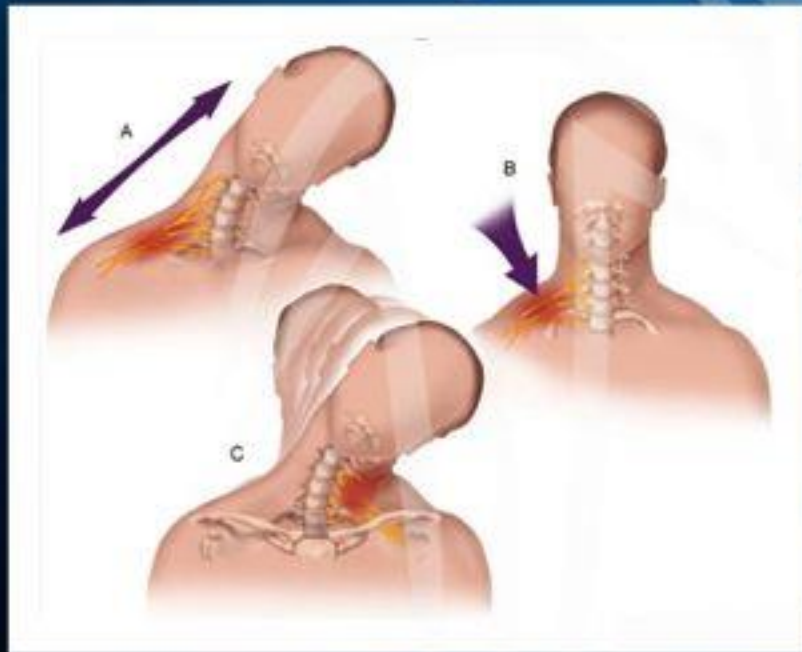
LUXAÇÃO

ART. ACROMIO-CLAVICULAR



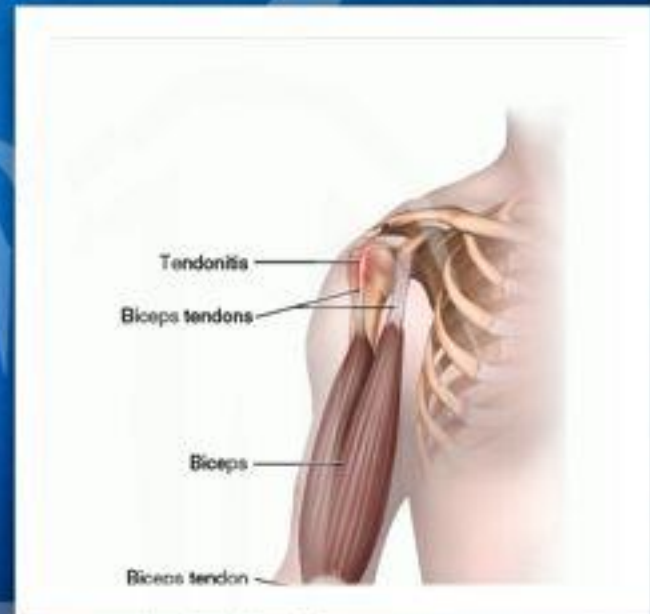
TESTE DE SPURLING

RADICULOPATIA CERVICAL



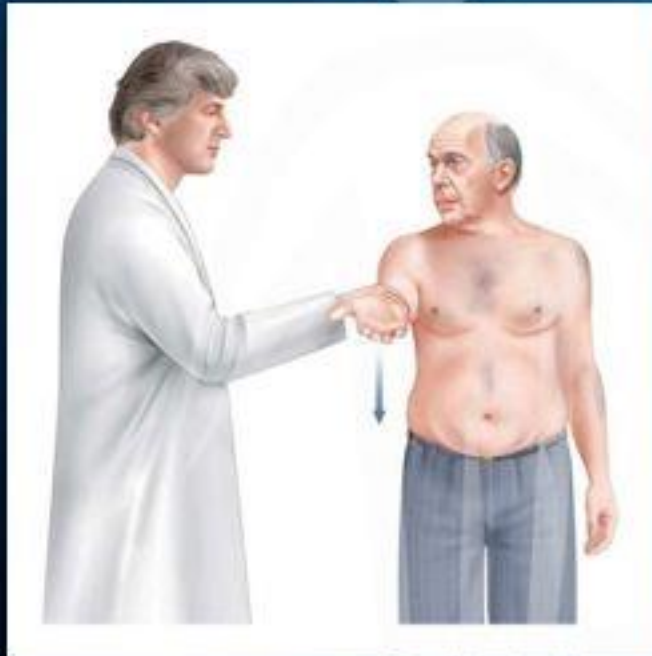
TESTE DE YERGASON

TENDINOPATIA DA CABEÇA LONGA DO BÍCEPS



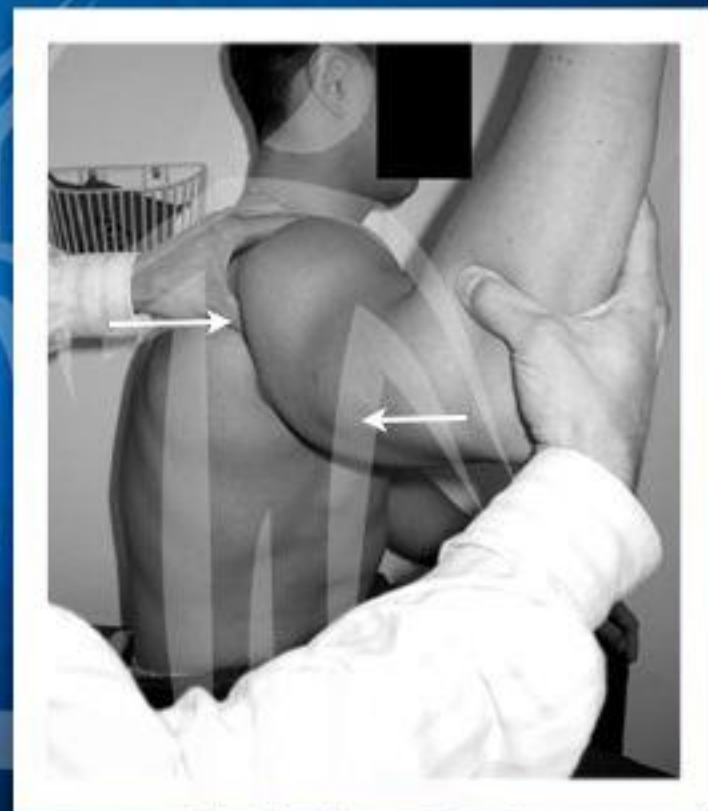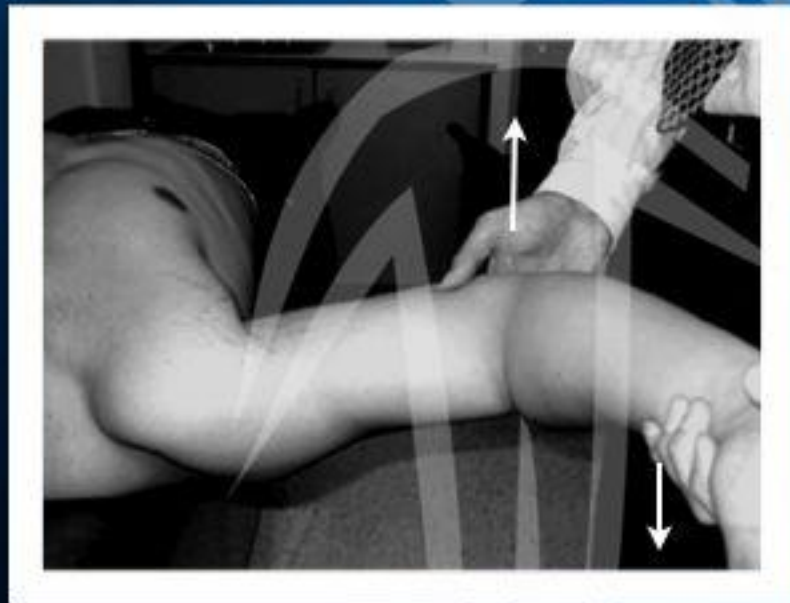TESTE DE SPEED

TENDINOPATIA DA CABEÇA LONGA DO BÍCEPS



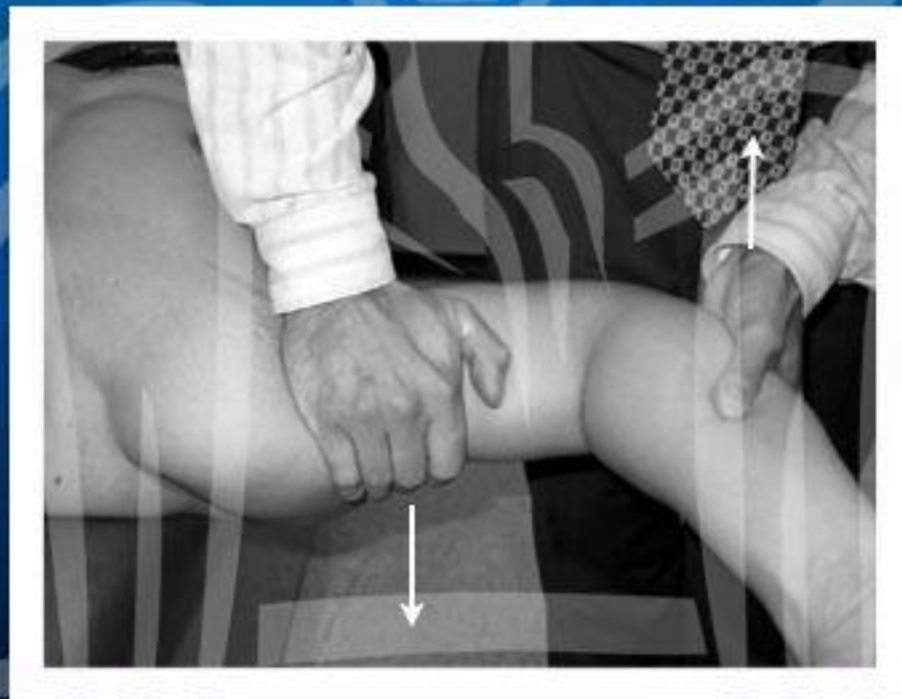TESTE DE APREENSÃO

INSTABILIDADE GLENOUMERAL



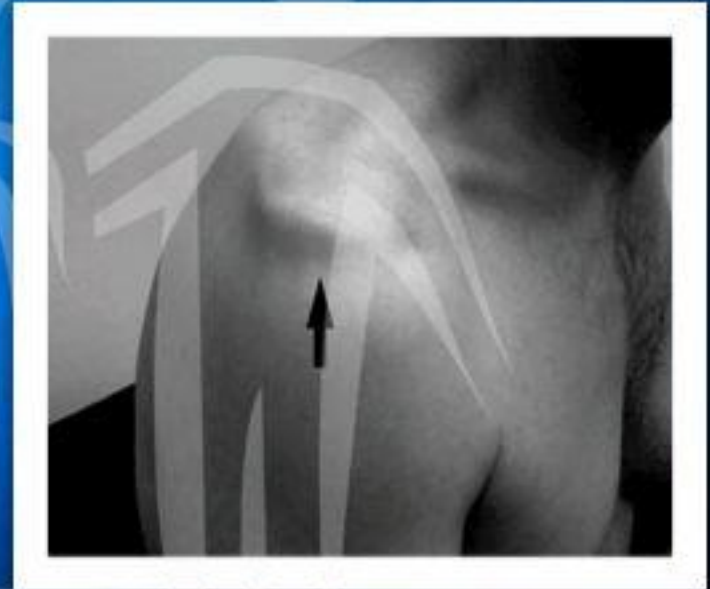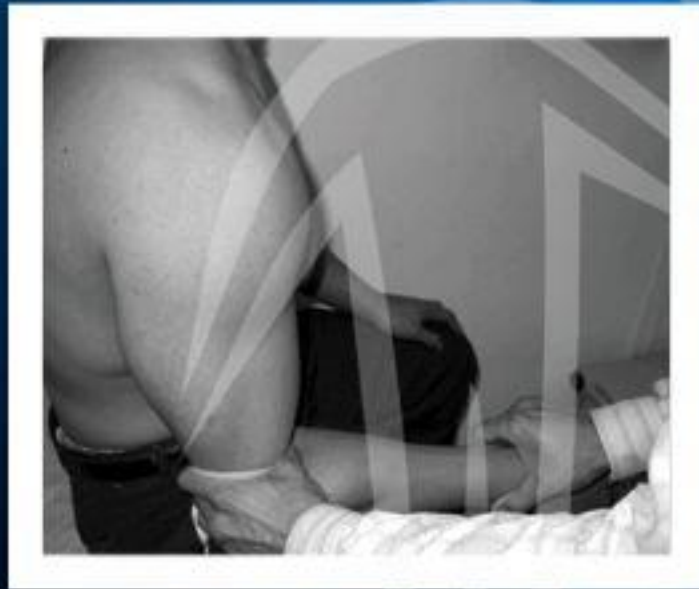TESTE DE REALOCAÇÃO

INSTABILIDADE GLENOUMERAL



SINAL DO SULCO

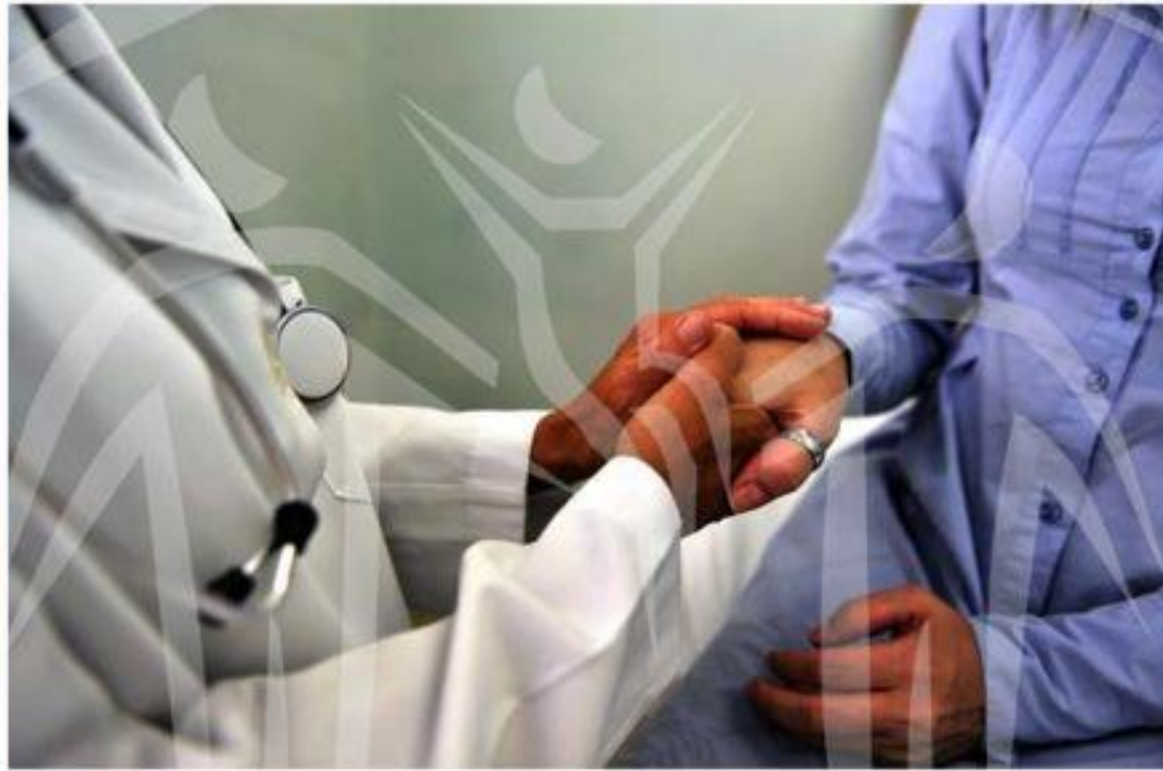INSTABILIDADE GLENOUMERAL



DOR NO OMBRO

PROBLEMAS

- Encaminhamentos para fisioterapia demorados
- 50% dos casos vão evoluir para cronicidade
- Grandes gastos com afastamentos do trabalho



Obrigado

Ortopedia
PARA
Médicos
DE
CLÍNICA
FAMÍLIA



Curso teórico-prático de oito horas, com foco no diagnóstico e manejo dos principais problemas ortopédicos clínicos pelo Médico de Família.

Informações pelo e-mail contato@alexandrefortes.com ou pelo telefone 48 - 95220793.